# Echokardiográfiás alapismeretek
# Kardiomiopátiák

*Dr.* Habon Tamás
*PTE KK I.sz.* Belgyógyászat
*Kardiológiai* Tanszék

# ACCF/ASE/AHA/ASNC/HFSA/HRS/SCAI/SCCM/SCCT/SCMR 2011 Appropriate Use Criteria for Echocardiography

A Report of the American College of Cardiology Foundation Appropriate Use Criteria Task Force, American Society of Echocardiography, American Heart Association, American Society of Nuclear Cardiology, Heart Failure Society of America, Heart Rhythm Society, Society for Cardiovascular Angiography and Interventions, Society of Critical Care Medicine, Society of Cardiovascular Computed Tomography, and Society for Cardiovascular Magnetic Resonance

*Endorsed by the American College of Chest Physicians*

| Cardiomyopathies With TTE | |
|---|---|
| • Initial evaluation of known or suspected cardiomyopathy (e.g., restrictive, infiltrative, dilated, hypertrophic, or genetic cardiomyopathy) | A (9) |
| • Re-evaluation of known cardiomyopathy with a change in clinical status or cardiac exam or to guide therapy | A (9) |
| • Routine surveillance (<1 y) of known cardiomyopathy without a change in clinical status or cardiac exam | I (2) |
| • Routine surveillance (≥1 y) of known cardiomyopathy without a change in clinical status or cardiac exam | U (5) |
| • Screening evaluation for structure and function in first-degree relatives of a patient with an inherited cardiomyopathy | A (9) |
| • Baseline and serial re-evaluations in a patient undergoing therapy with cardiotoxic agents | A (9) |
| **Ischemic Cardiomyopathy/Assessment of Viability With Stress Echocardiography** | |
| • Known moderate or severe LV dysfunction<br>• Patient eligible for revascularization<br>• Use of dobutamine stress only | A (8) |

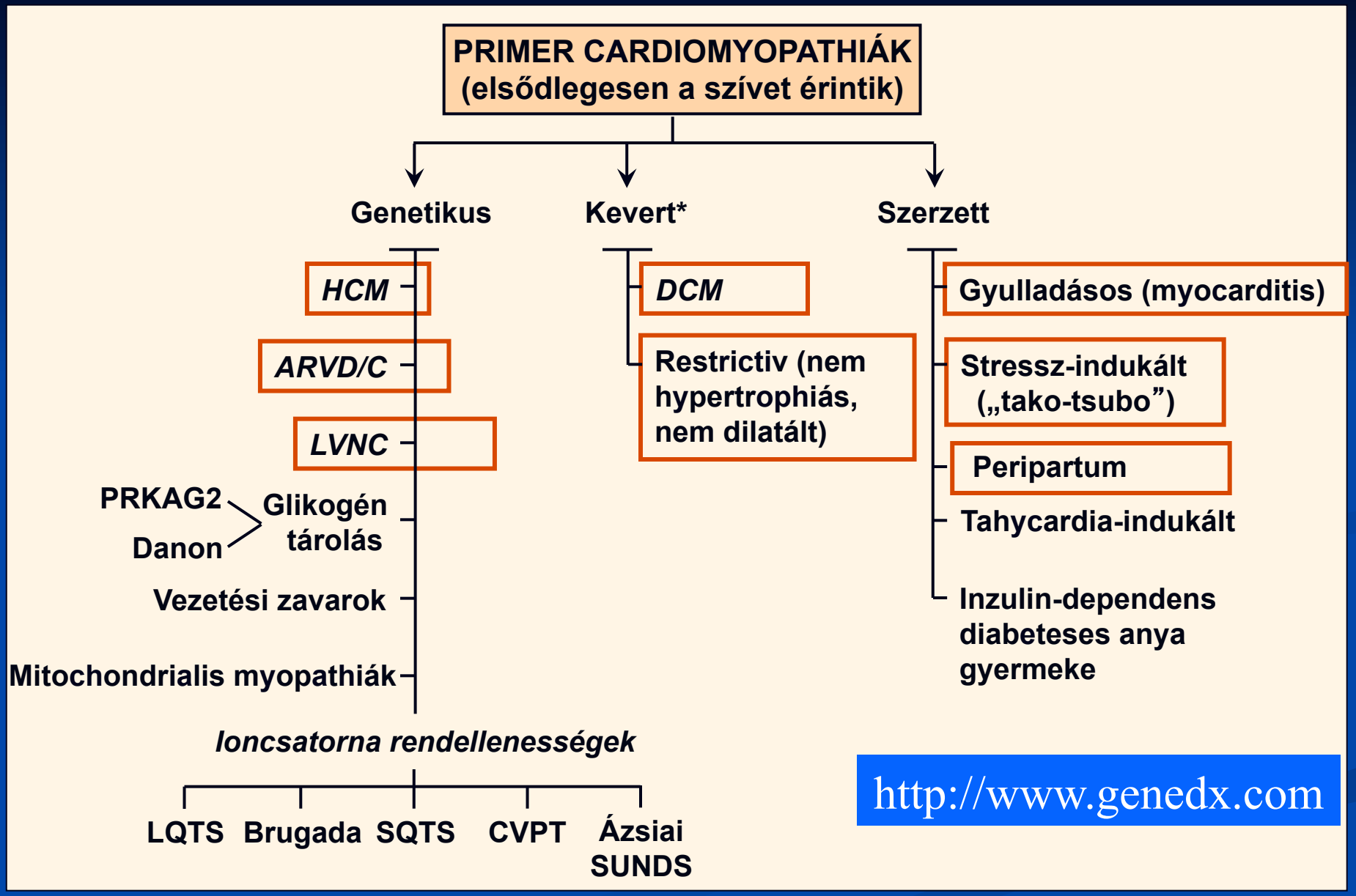


*Maron BJ et al; Circulation 2006;113:1807-1816*

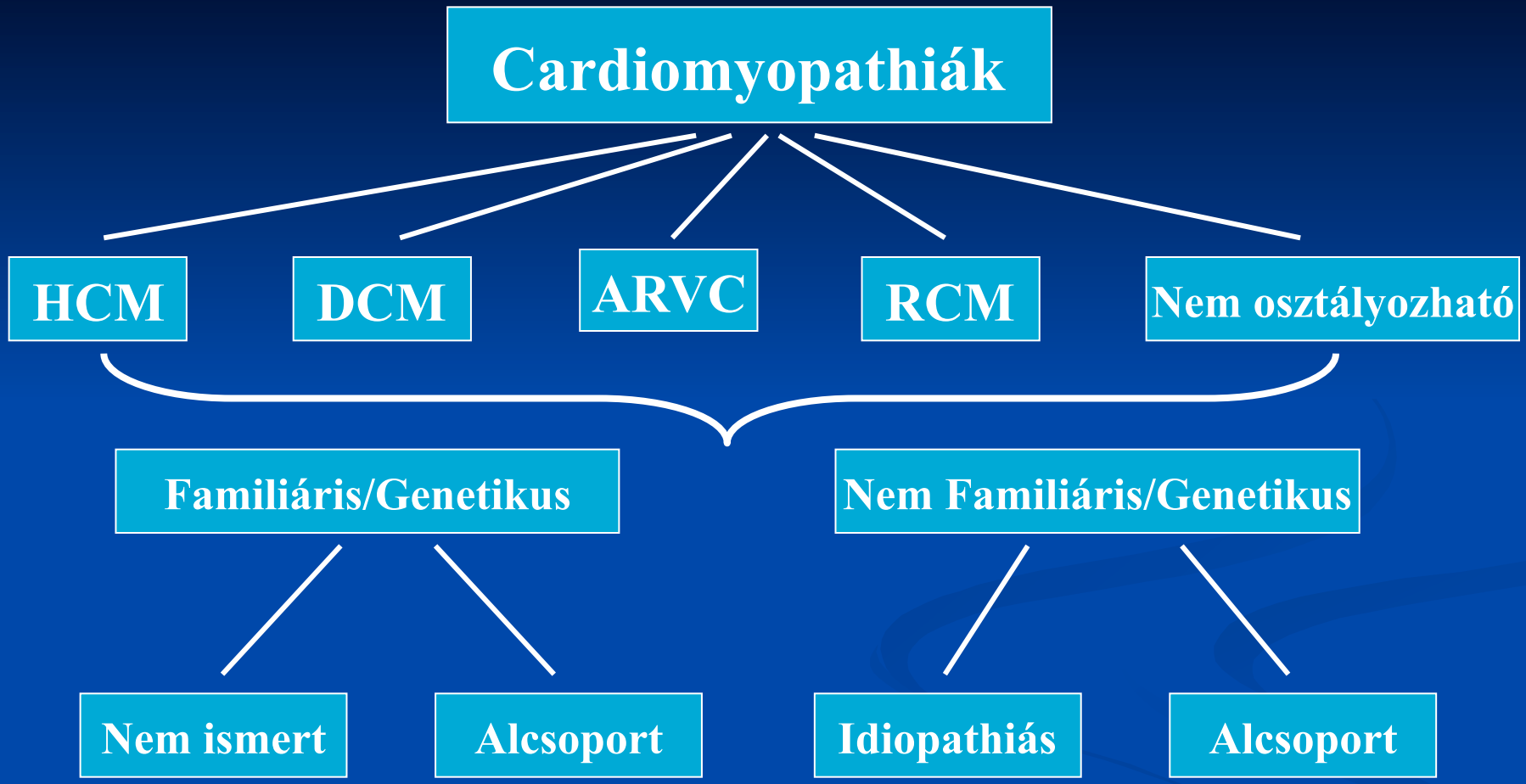


Classification of the cardiomyopathies: a position statement from the European Society Of Cardiology Working Group on Myocardial and Pericardial Diseases. **Eur Heart J. 2008; 29:270-276.**

# CM: Specifikius etiológiák

- Ischemic
- Valvular
- Hypertensive
- Inflammatory
- Metabolic
- Inherited
- Toxic reactions
- Peripartum

Ischemic: thinned, scarred tissue

# DCM

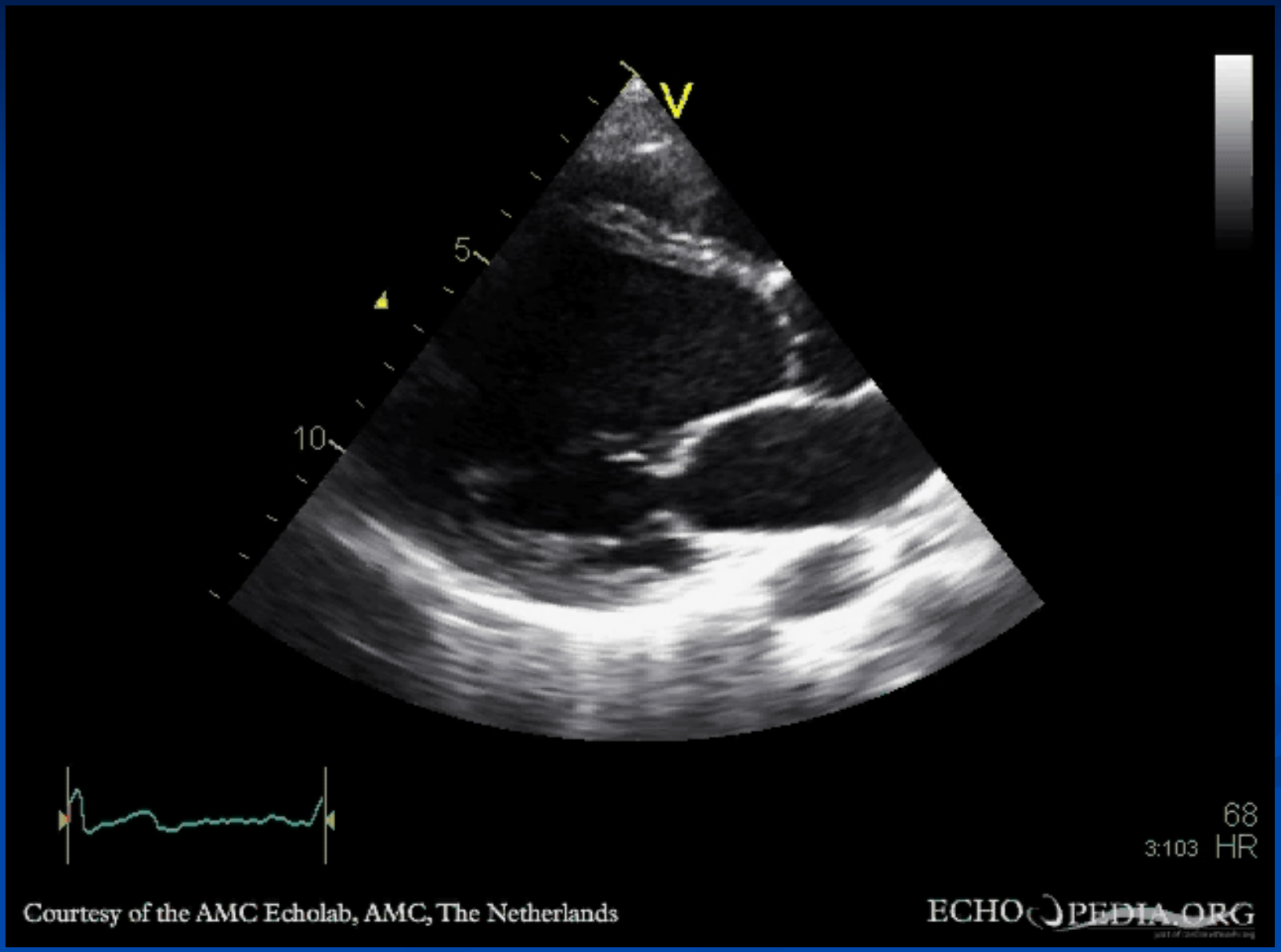
V
5
10
68
3:103 HR
Courtesy of the AMC Echolab, AMC, The Netherlands
ECHOPEDIA.ORG

# DCM echocardiográfiás jellemzői

- Bal kamrai dimenziók
  - Átmérő
  - Spericitás
- Bal kamra systoles funkciója
  - EF
  - CO
  - dP/dt
- Segmentális falmozgászavarok
  - Etiológia??
  - Stress echo
- Bal kamra diastoles funkciója
  - E/A
  - E/E'
- Mitrális regurgitáció
  - Funkcionális
  - Ischemiás
- Bal kamrai thrombus
- Jobb kamra funkció
  - TAPSE
- Pulmonális nyomás
  - IVC
  - TR

# Hogyan mérjük a bal kamrai átmérőket?

- Ínhúrok szintjében, merőlegesen az elképzelt hossztengelyre

- 2D irányított M-mód
  - parasternális hossztengely
    - Falak merőlegesek a sugáriránya
  - Esetleg parasternális rövid tengely
- Jobb időbeli felbontás (magasabb frame rate)
- Gyakran „off axis”

- 2D
  - Parasternális hossztengely
  - Csúcsról lehetőleg ne!
- Rosszabb időbeli felbontás
- Minden esetben merőleges a képzeletbeli hossztengelyre

# Átmérők: 2D irányított M-mód

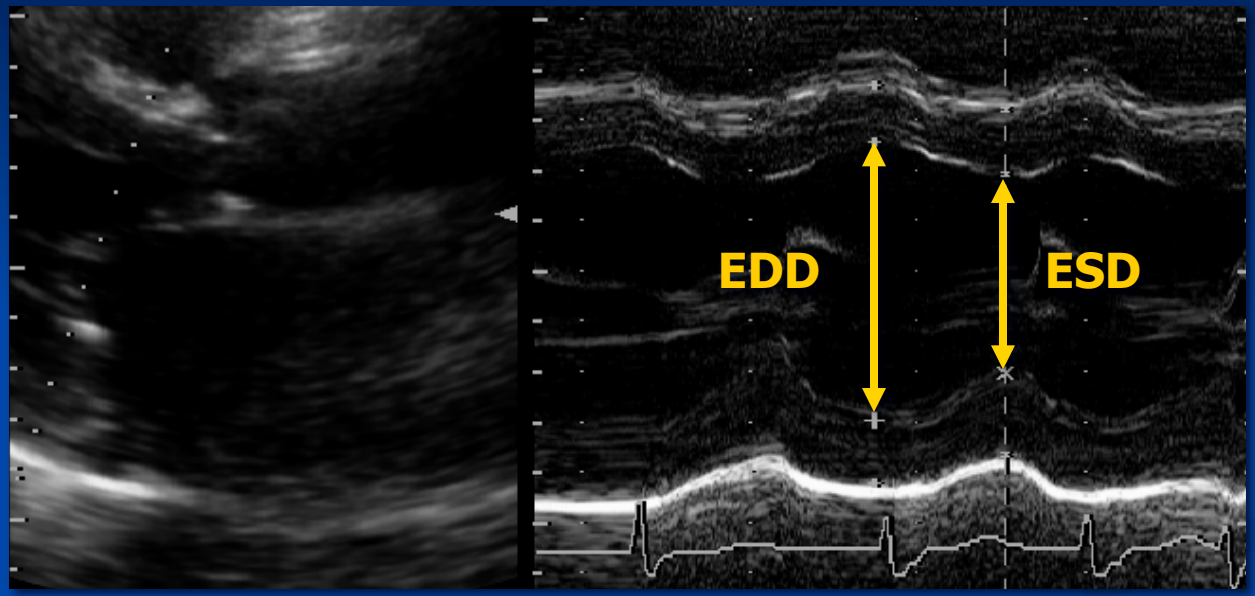


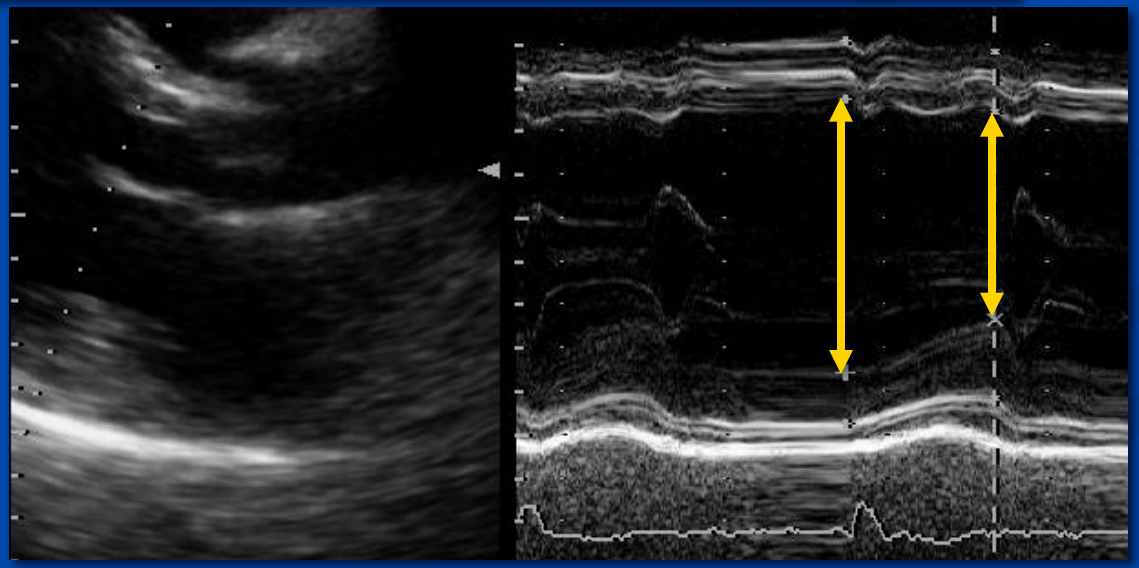

- Végdiastole
  - QRS kezdete
- Végsystole
  - Legkisebb átmérő
  - Aszinkronia esetén a posterior fal mozgása számít

# Sphericity index

- Normálisan a hosszátmérő és rövidebb átmérő aránya > 1.6.
- DCM-ben < 1.5, akár egyenlő is lehet
- Prognosztikus szerepe van

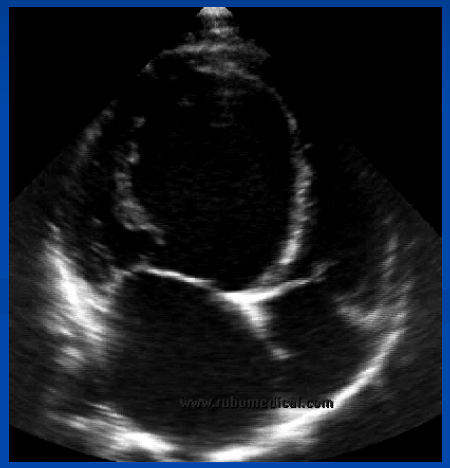

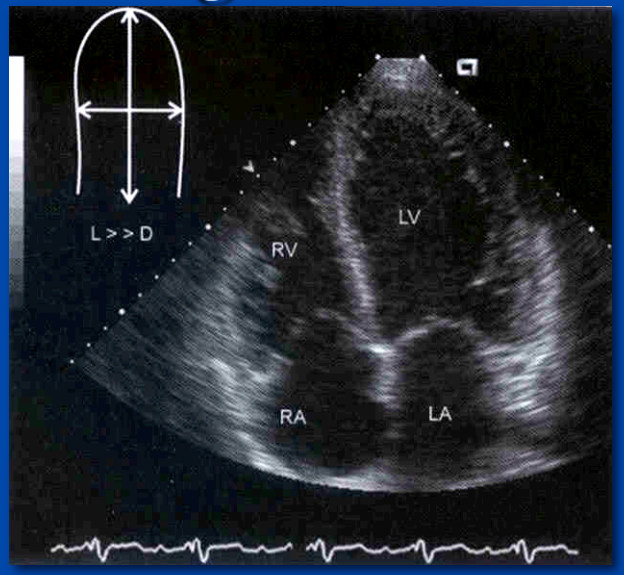


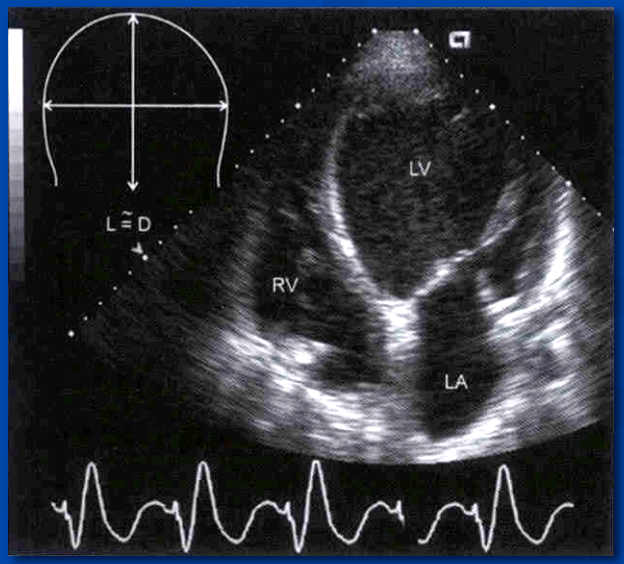

# Ejekciós frakció: Simpson módszer

- Biplane módszer:
  - Az egymásra kb. merőleges csúcsi 4,-ill. 2-üregi metszetben mérünk areat
- Csak jól látható vér-endocardium határ esetén pontos!
- Papilláris izmot és trabeculákat volumenként rajzoljuk
- 3D!!! Kontraszt

**EDV** **ESV**

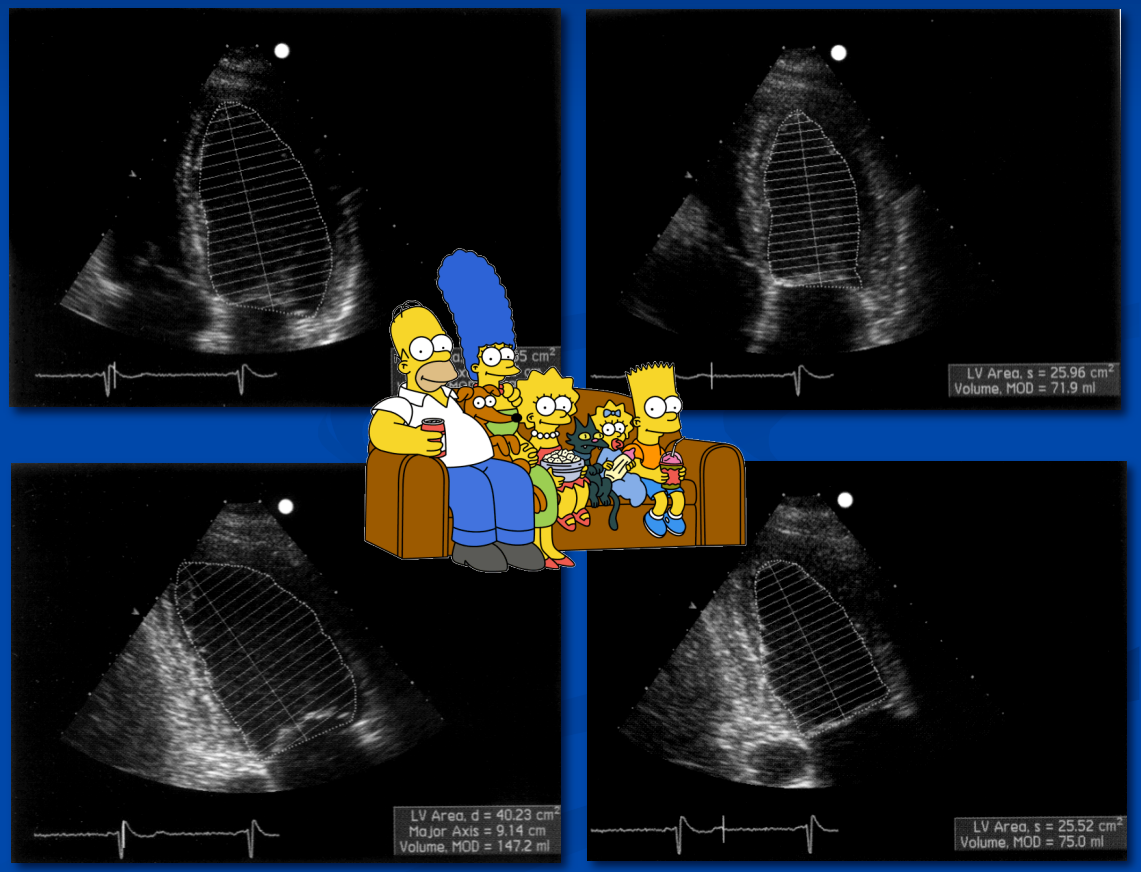

# Contrastecho


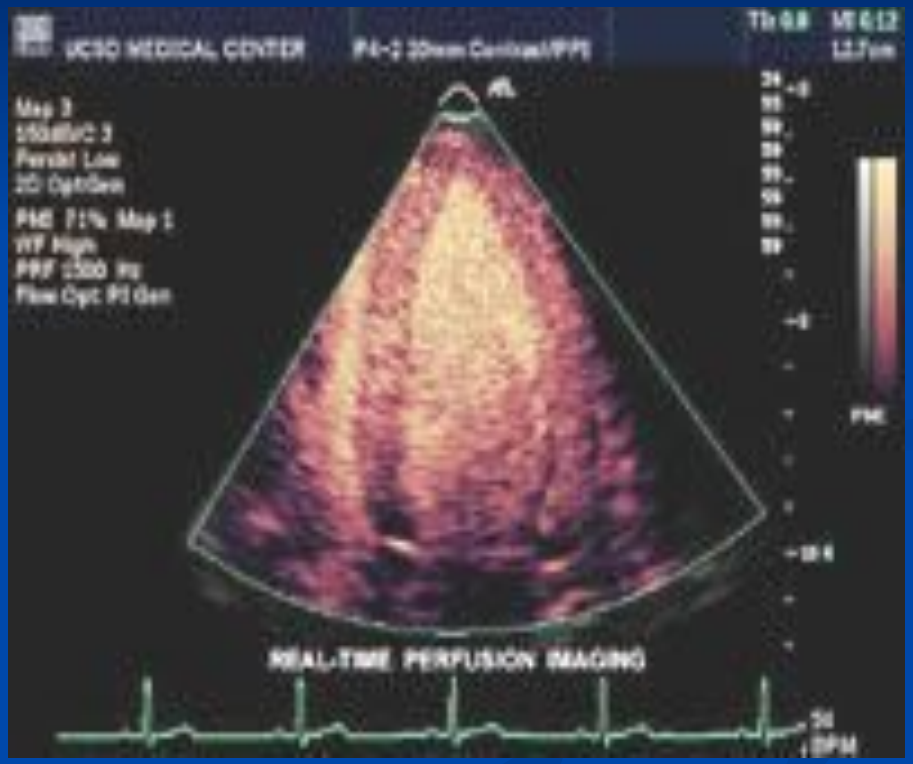

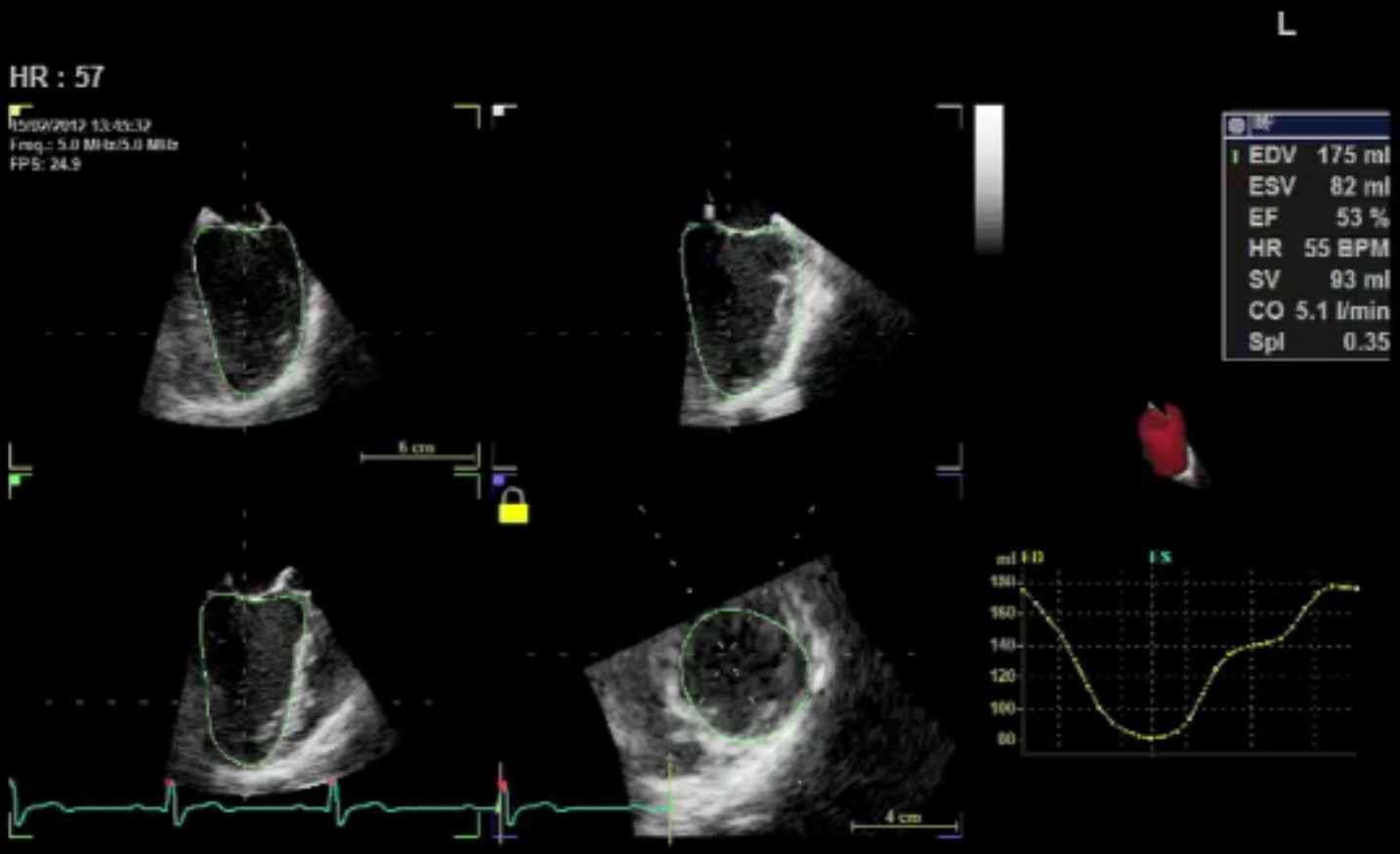
L
HR : 57
FPS: 24.9
EDV 175 ml
ESV 82 ml
EF 53 %
HR 55 BPM
SV 93 ml
CO 5.1 l/min
SpI 0.35
5 cm
4 cm

# CO: hogyan mérjük?

- LVOT átmérő mérése systoleban, parasternális hossztengelyi nézetben
- Átmérőből LVOT areat számolunk
- $D^2$: a mérési hibát is négyzetre emelem!

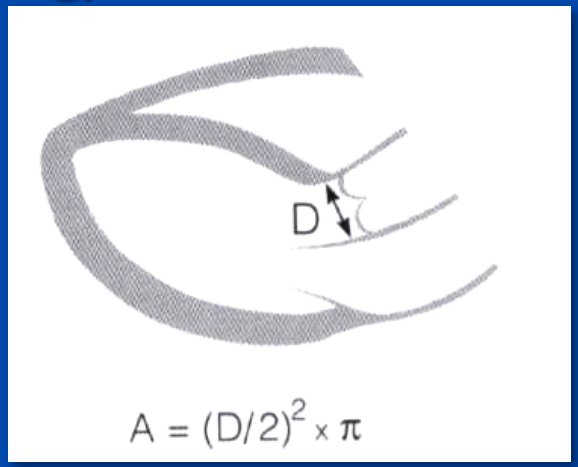


- VTI: távolság jellegű paraméter
- Csúcsi ötüregű nézetből az LVOT-ban, pulzatilis Dopplerrel!
- 3 (5) mérést átlagolunk

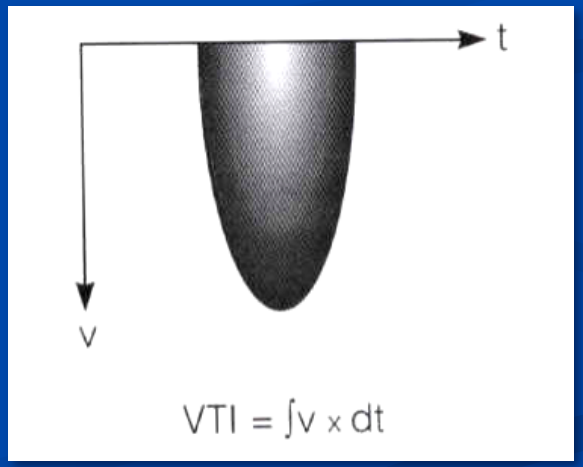


**SV = VTI x A**

# Globális systoles functio: dP/dt hogyan mérjük?

- MI sebesség spectrum CW-vel mérve
- Mennyi idő telik el az 1 m/s és a 3 m/s sebesség elérése között (32 Hgmm-nyi nyomásemelkedés)

$$dP/dt = \frac{32}{\Delta t}$$

- Hosszabb $\Delta t$ ill. alacsonyabb dP/dt (< 600 Hgmm/sec) károsodott BKF-ra utal

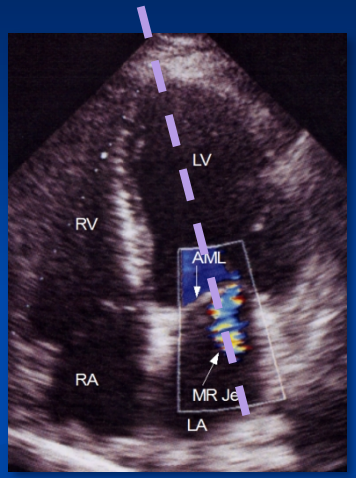


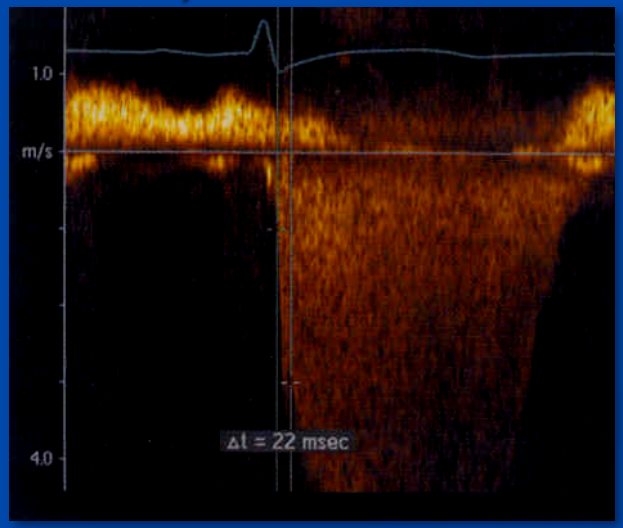


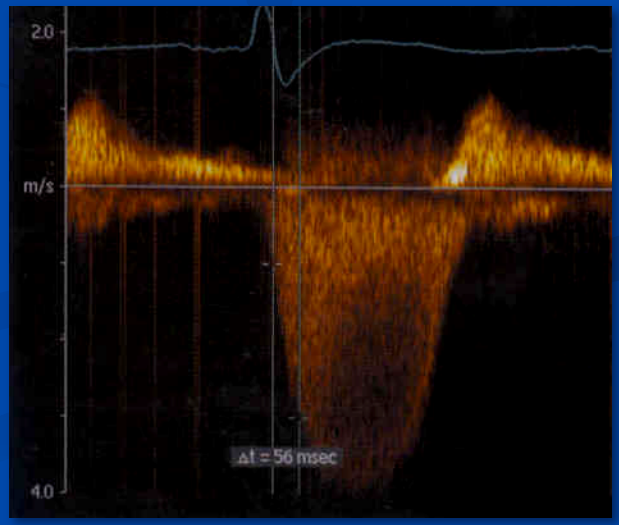

# Diastolés funkció megítélése


Normális Károsodott relaxáció Pseudonormális Restriktív

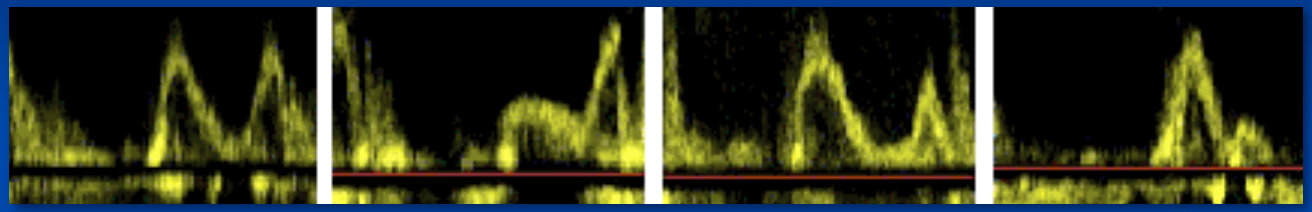

- A mitrális beáramlási görbe preload-függő, a normális és pseudonormális görbe nem megkülönböztethető

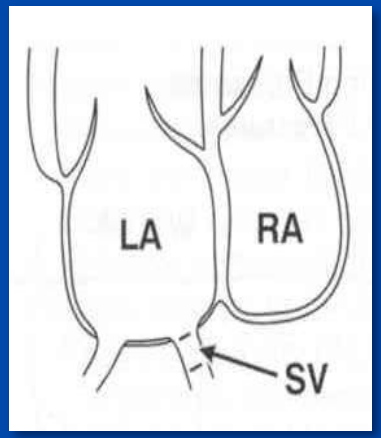


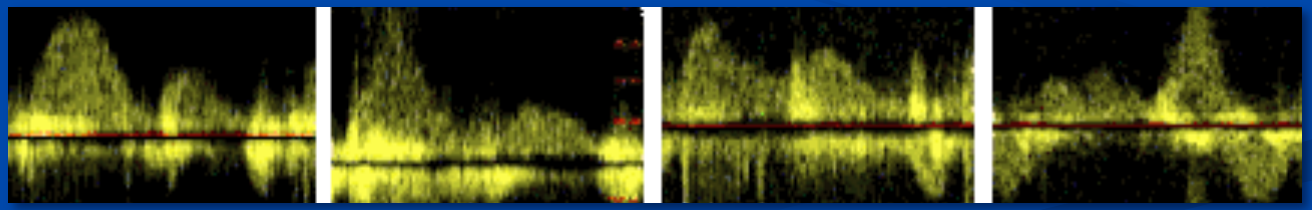

- Klasszikusan a véna pulmonális beáramlási görbe segít a feladat megoldásában

# Diasztolés funkció megítélése

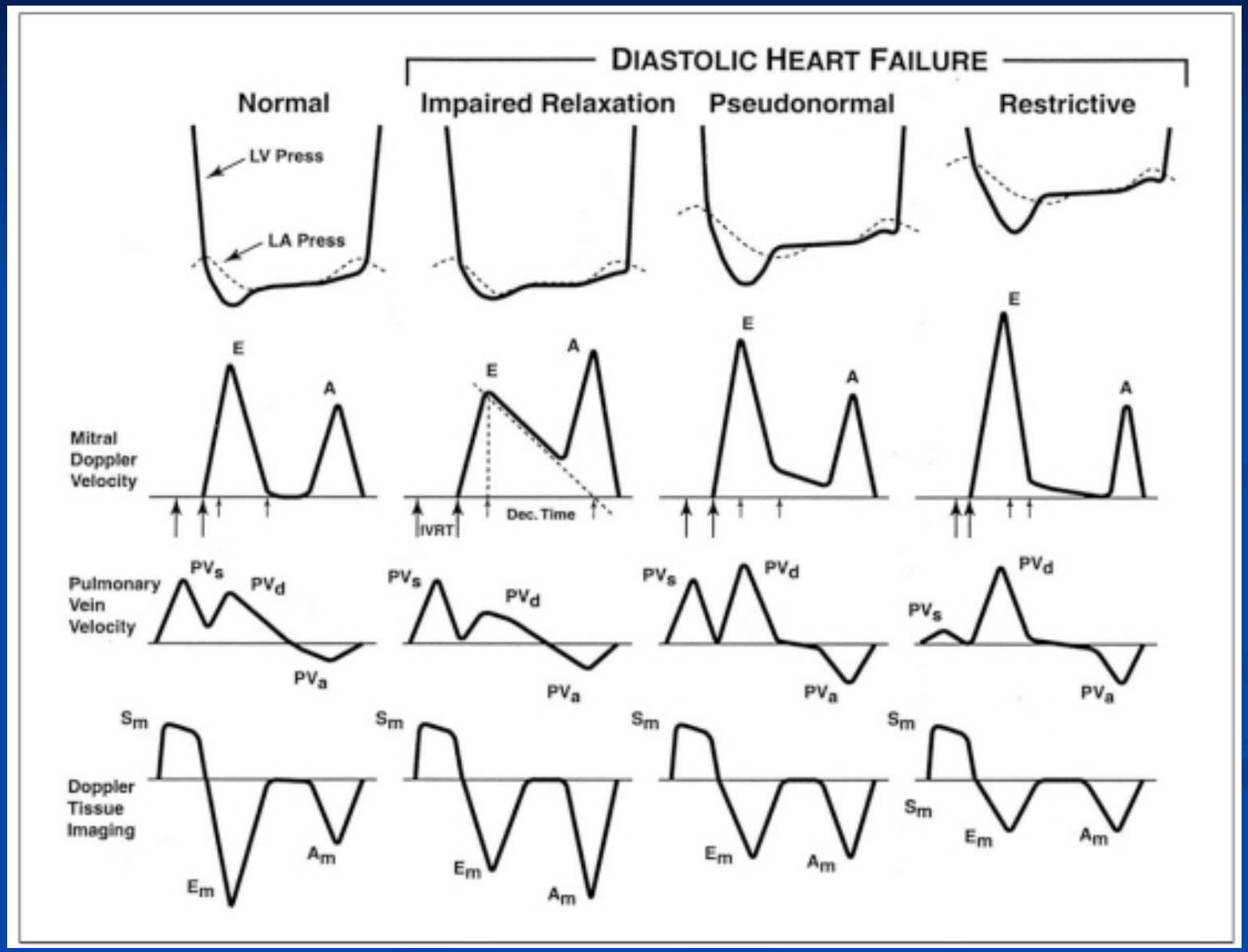

# E/E’ szerepe

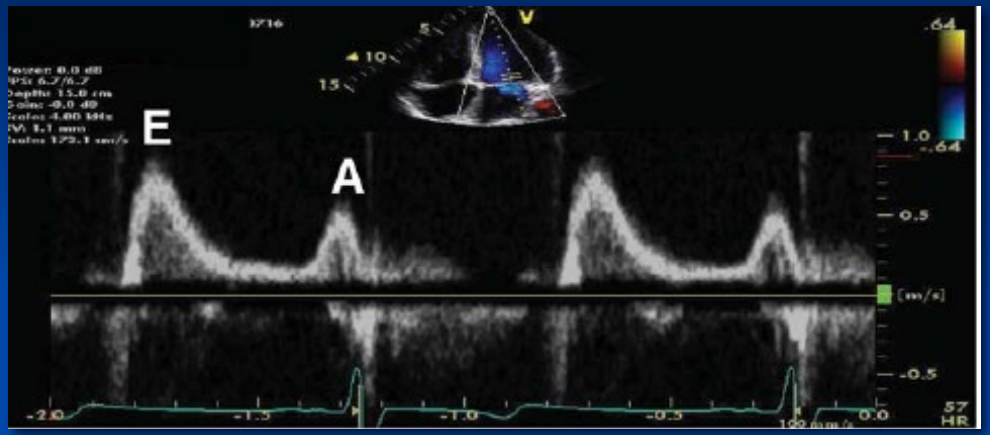


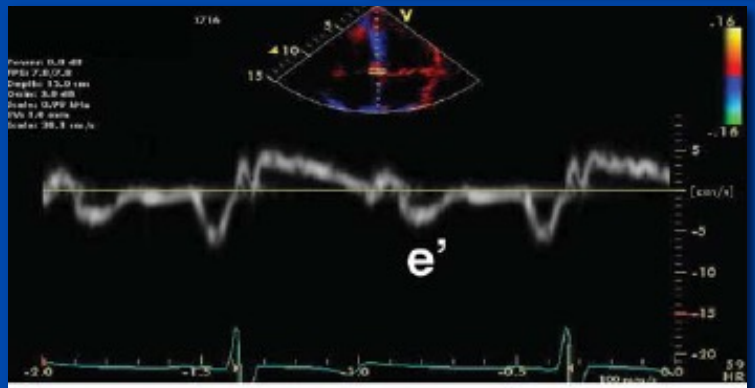


Septal E/e’ = 80/4 = 20

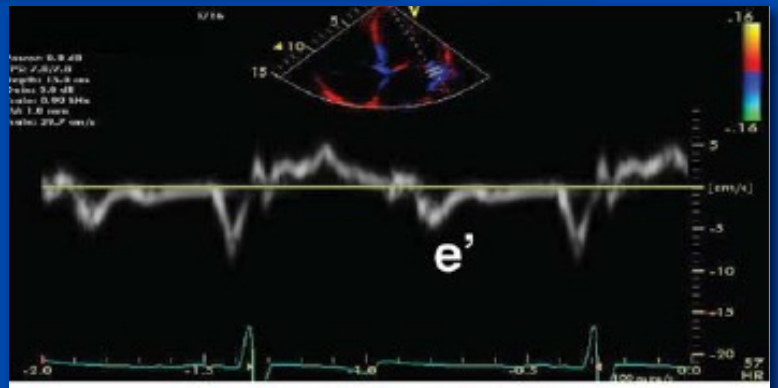


Lateral E/e’ = 80/5 = 16

- Az emelkedett E/E’ emelkedett bal kamrai töltőnyomásra utal. Segíthet a normális és pseudonormális mitrális beáramlási görbe elkülönítésében

# Non-ischemiás DCM: funkcionális mitrális regurgitáció

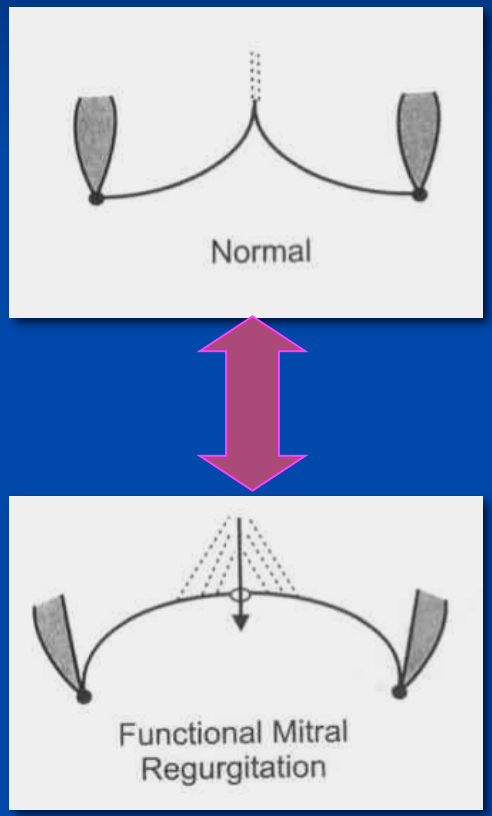


- A gömbszerű kamrában a papilláris izmok apicalis, laterális irányba tolódnak el, ami a mitrális felfüggesztő apparátus megrövidülését eredményezi


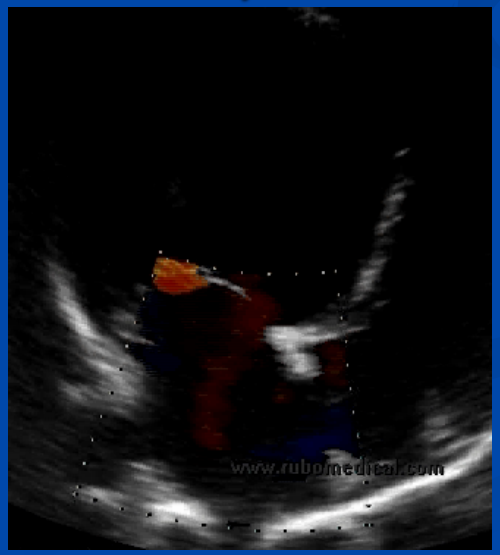


- A vitorlák koaptációja romlik, ami többé-kevésbé centrális regurgitációs jet-et eredményez

# Ischemiás eredetű mitrális regurgitáció

- Ischemiás szívben az egyik mitrális vitorla hegesedik, mozgásában korlátozottá válik
- Gyakrabban a posterior vitorlát érinti inferior infarctus vagy ischemia talaján

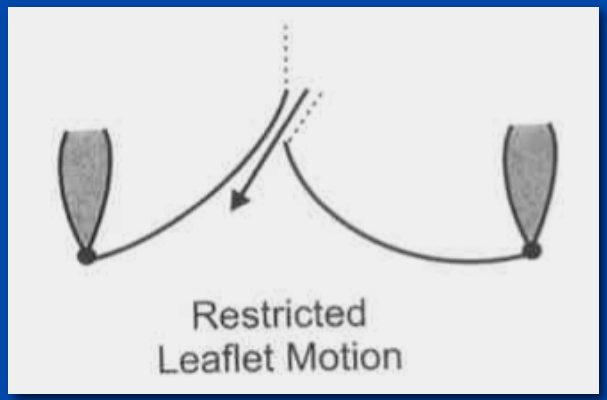


- A mellső vitorla prolapsusát utánozza, excentrikus jet-et eredményez
- Itt nem „az ép alá fúj”!

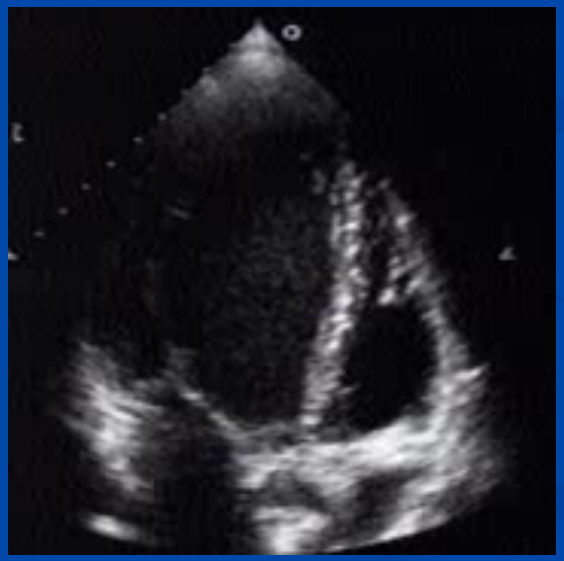

# Mitral regurgitation

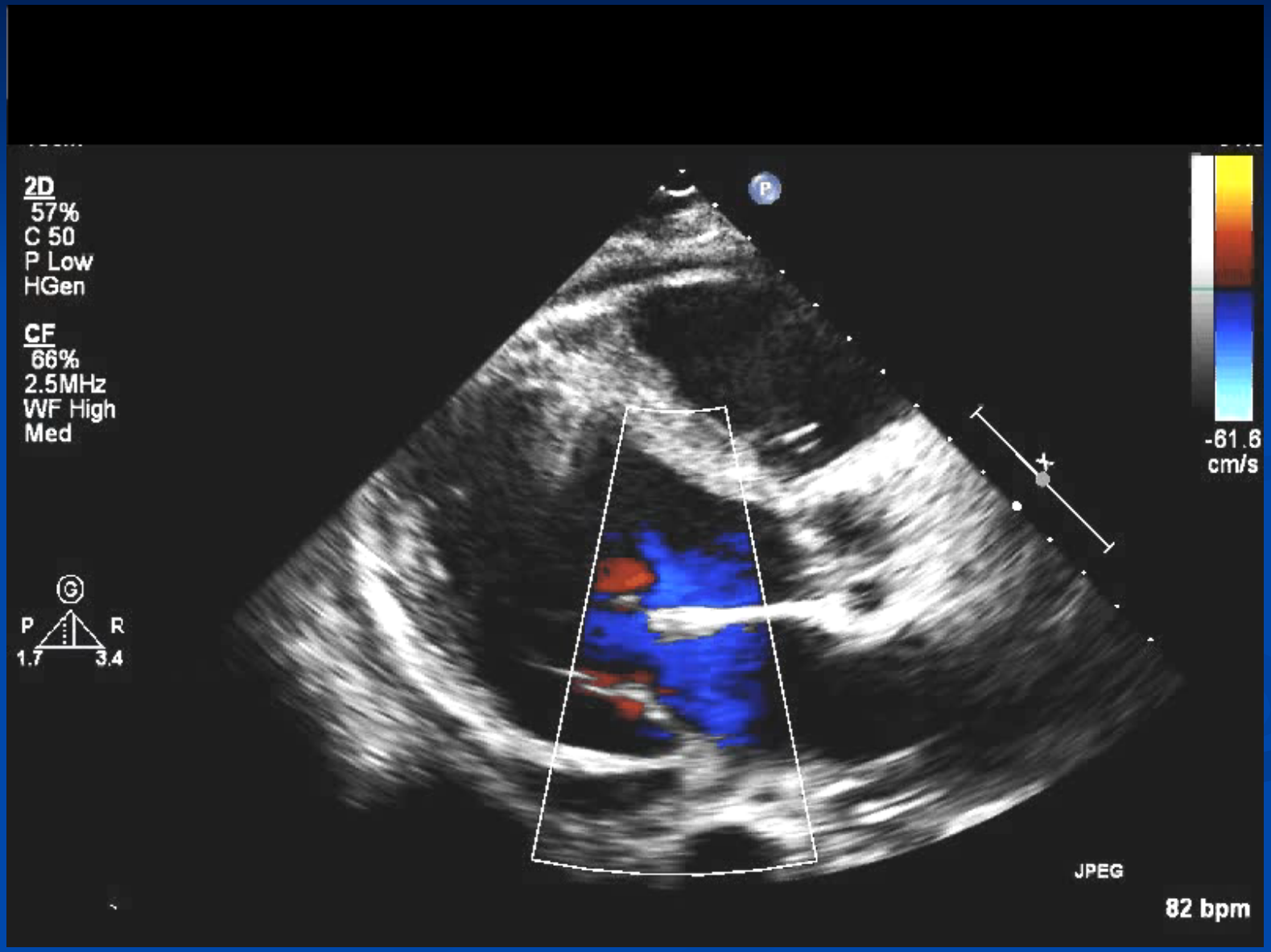

# Bal kamrai thrombus

- Ischemiás DCM-ben, szegmentális falmozgászavar esetén a bal kamrai thrombus gyakoribb
- Non-ischemiás DCM-ben, diffúz hypokinesis esetén is előfordul

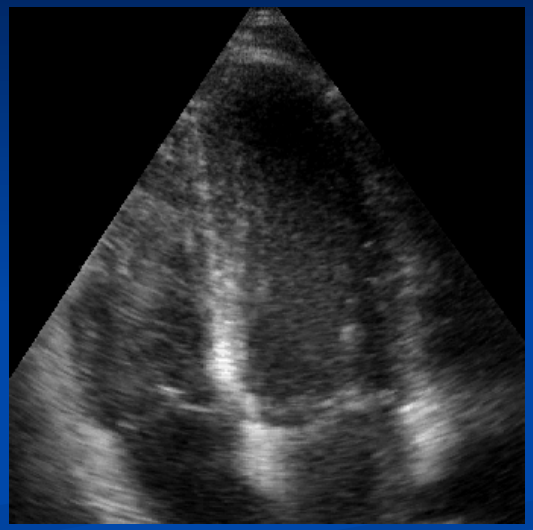


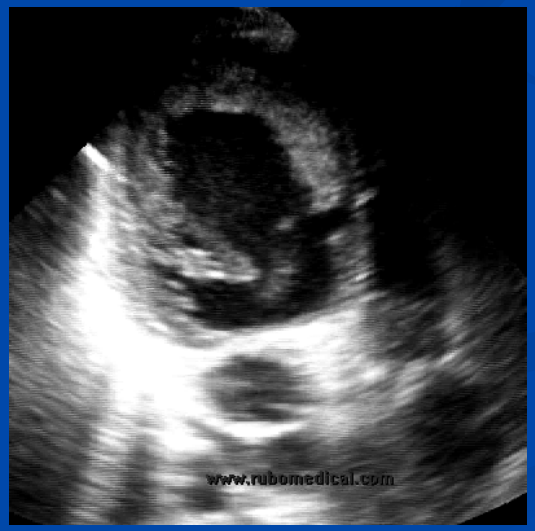


- A spontán echokontraszt pre-thromboticus állapot, de thrombus nem minden esetben van jelen

# DCM - SEC

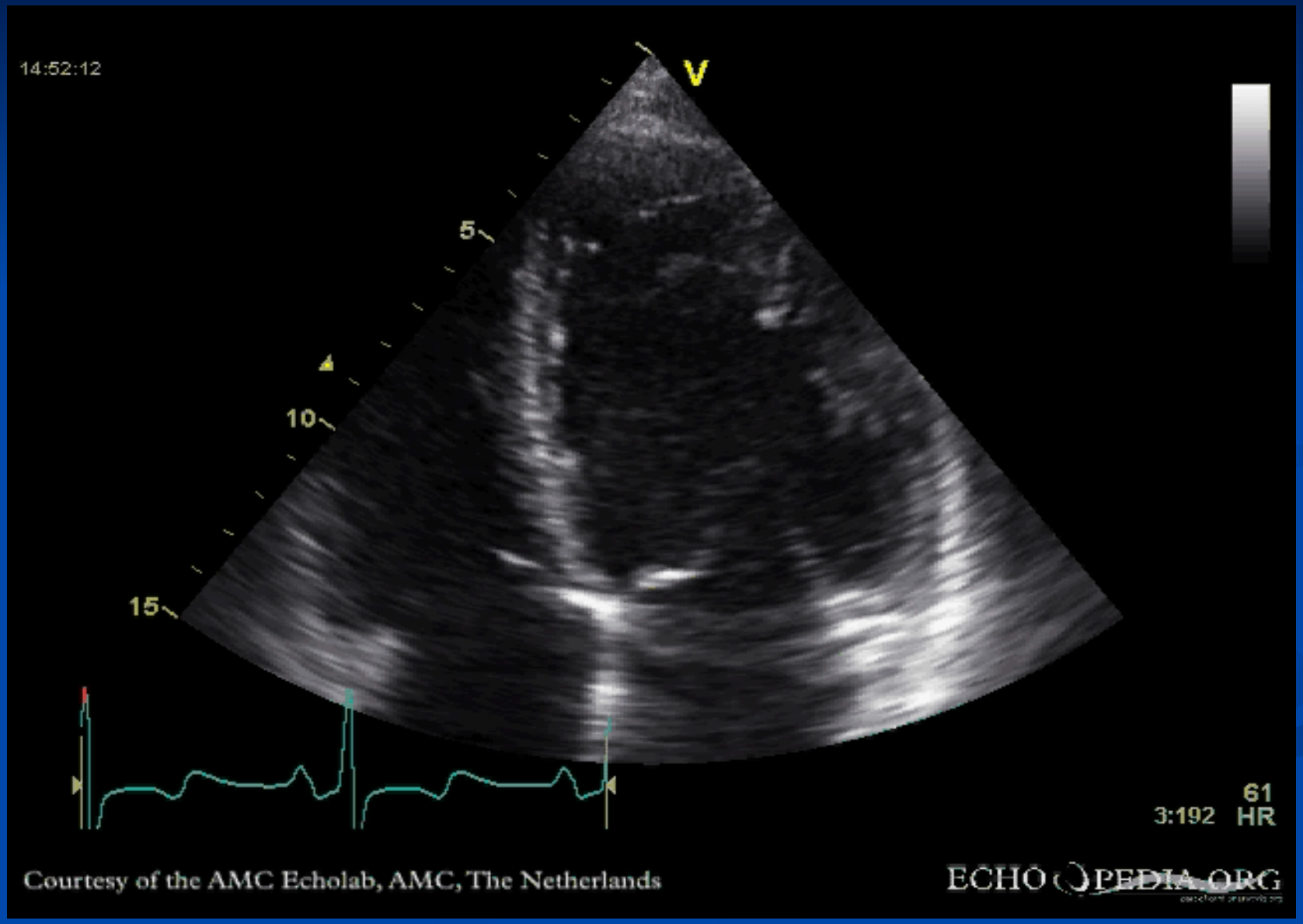
14:52:12
V
5
10
15
61
3:192 HR
Courtesy of the AMC Echolab, AMC, The Netherlands
ECHOPEDIA.ORG

# Bal kamrai thrombus

- Ischemiás DCM-ben, szegmentális falmozgászavar esetén a bal kamrai thrombus gyakoribb
- Non-ischemiás DCM-ben, diffúz hypokinesis esetén is előfordul

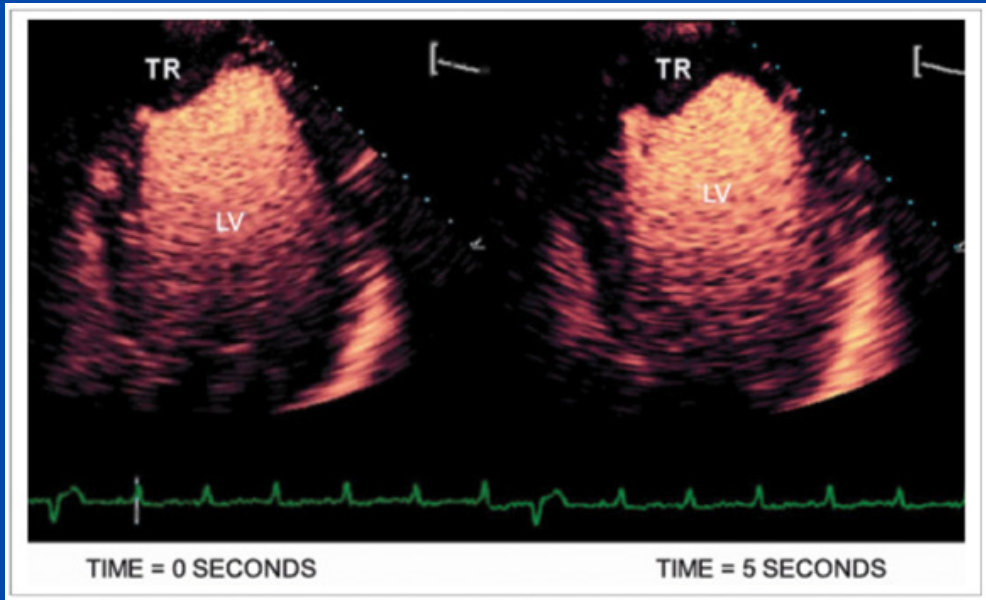


*Figure 5 - Contrast echocardiography showing dilated left ventricle, with no contrast filling at ventricular apex (non-vascularized), suggesting apical thrombus.*

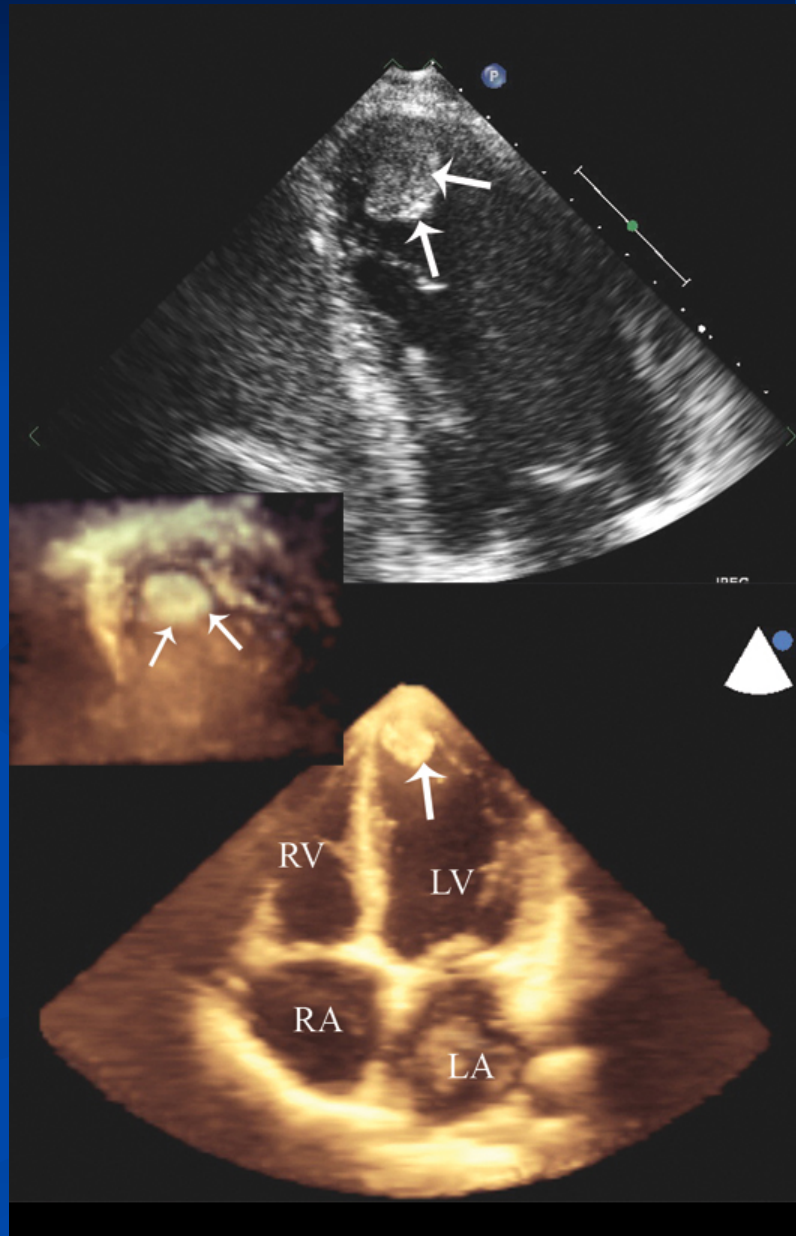

# Jobb kamra funkció


- Tricuspid annular plane systolic excursion ( **TAPSE**)
  - Kóros < 24 mm
  - < 14 mm igen rossz prognózist jelent

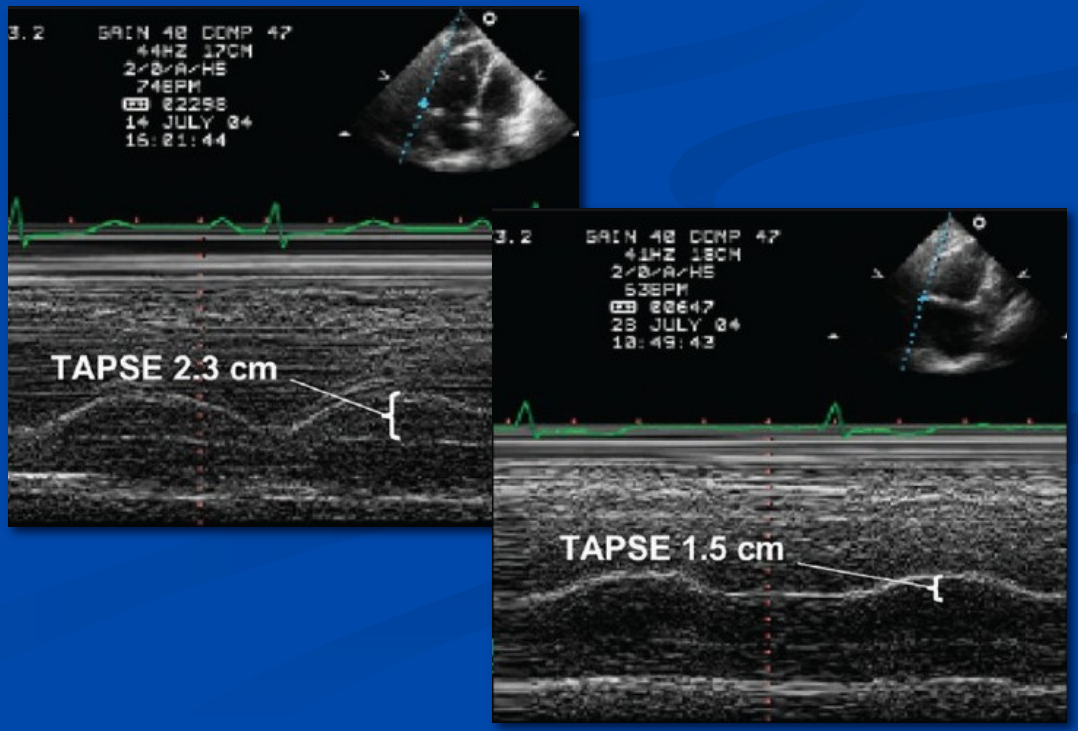


- A jobb kamra funkció károsodása rosszabb prognózist jelent

# Jobb kamra nehézségei

## 2D, 3D, TAPSE, Doppler

Előről nézve háromszög alakú

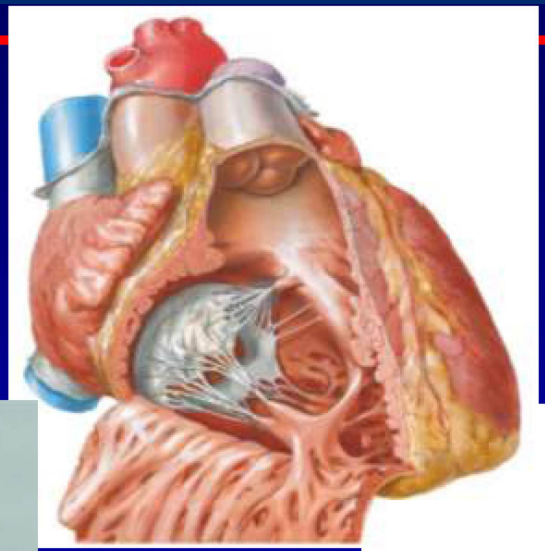

Keresztmetszetben félhold alakú

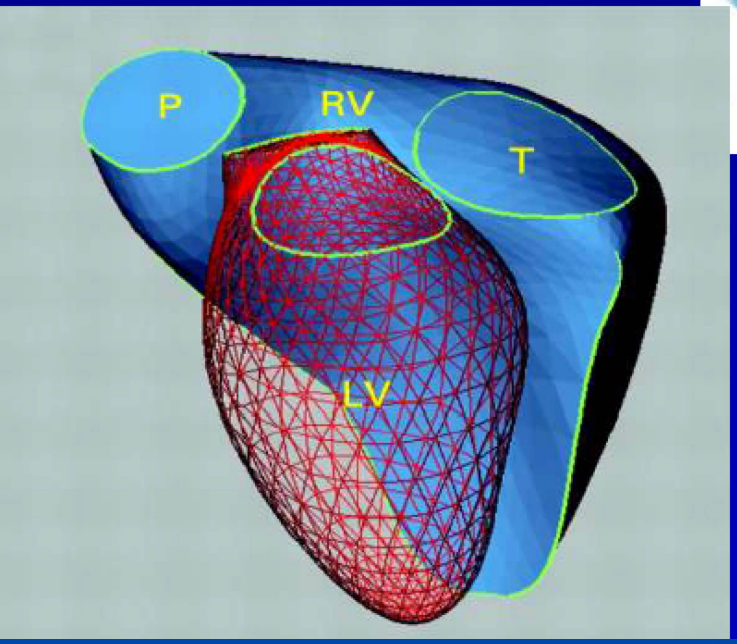


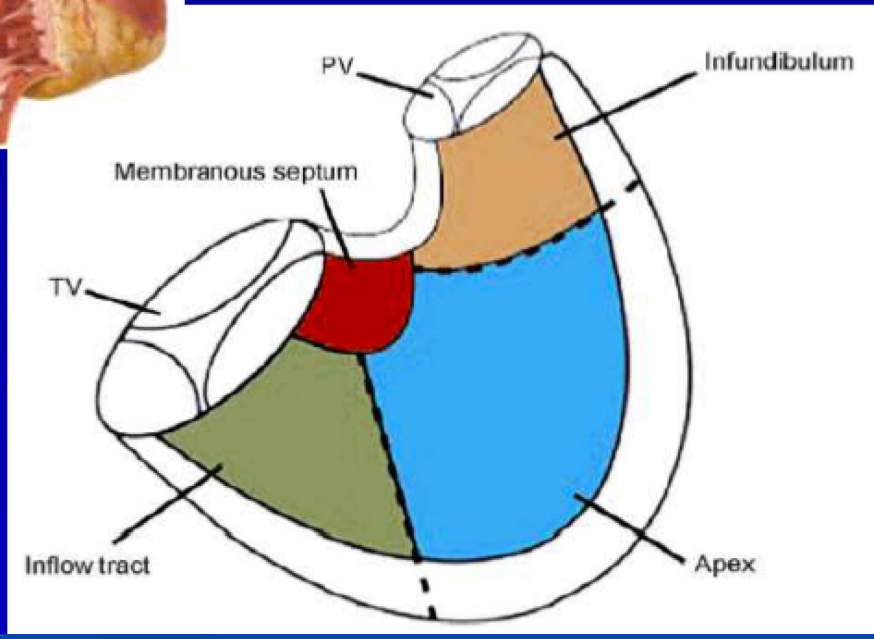

# Pulmonális nyomás

- Emelkedése rosszabb prognózist jelent
- A tricuspidalis insuffitientia sebességéből indirekt módon kiszámolható a jobb kamrai systolés nyomás
  - Systolés PAP= $4v^2$+RA nyomás
- Több nézetből nézzük meg
- Pulmonalis stenosis vagy RVOT obstructio jelenlétében nem reális

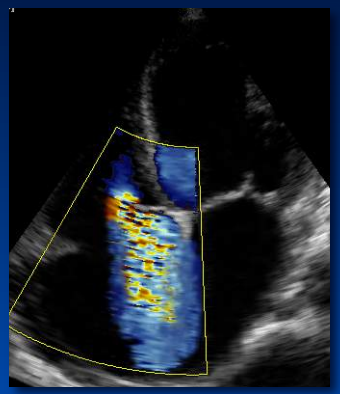

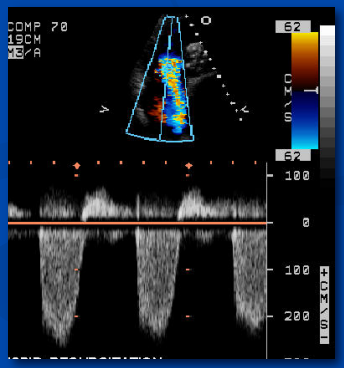


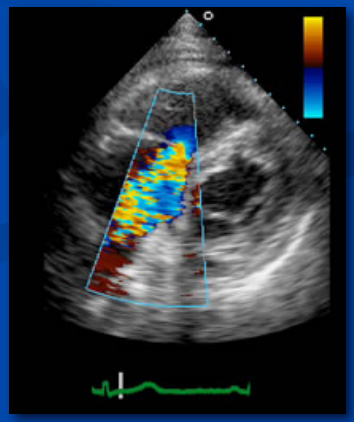

# Jobb pitvari nyomás becslése

- IVC tágassága ill. az átmérő változása belégzésben

| IVC size | Collapsibility Index | RA Pressure |
|---|---|---|
| Normal IVC size (≤1.7 cm) | 50% decrease in size | 0 - 5 mm Hg |
| Dilated IVC (>1.7 cm) | ≥ 50% inspiratory collapse | 6 – 10 mm Hg |
| | < 50% inspiratory collapse | 10 – 15 mm Hg |
| | no collapse | > 15 mm Hg |

**Source:** Lang RM, Bierig M, Devereux RB, et al. Journal of the *American Society of Echocardiography 18:1458, 2005.*

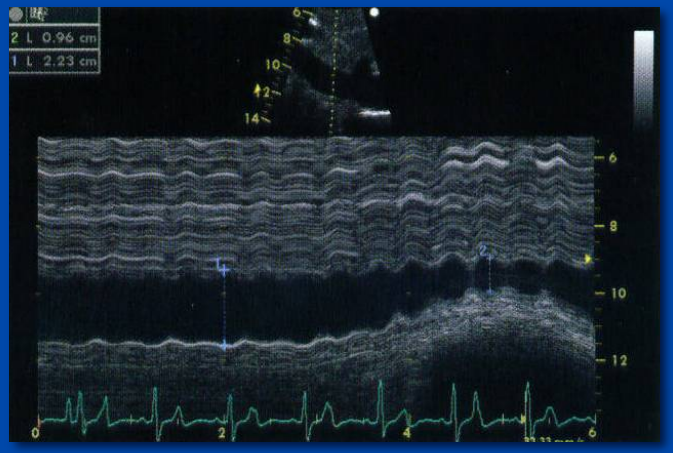


# „Free” tricuspidális regurgitáció

- Erősen dilatált jobb kamra, vagy a tricuspidális billentyű organikus betegsége esetén a jobb kamra és pitvar közötti nyomáskülönbség kicsi

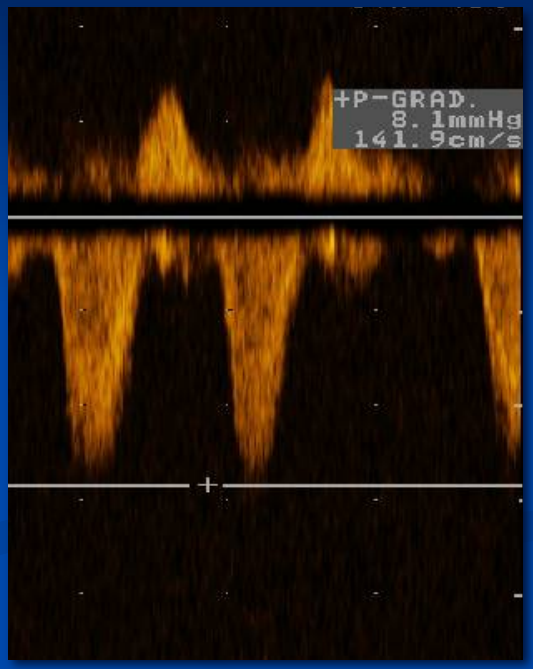


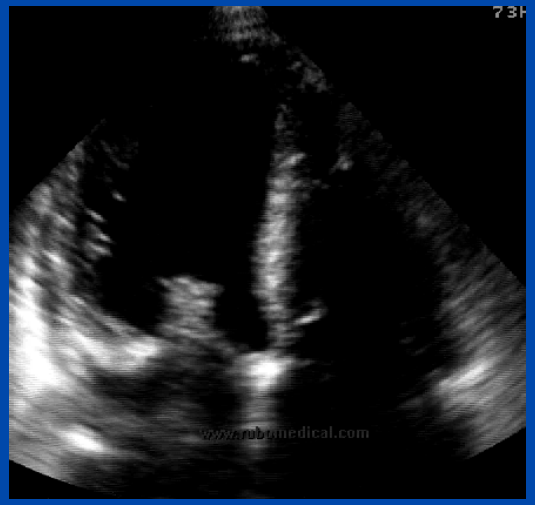

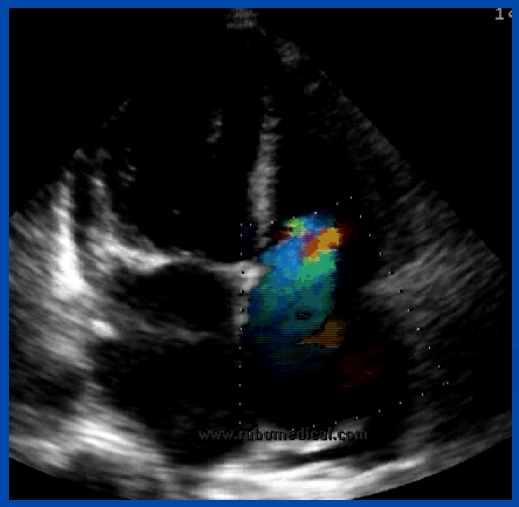

- A tricuspidális regurgitáció sebessége is alacsony. Az ebből kalkulált nyomás nem tükrözi a pulmonális nyomást

# CRT

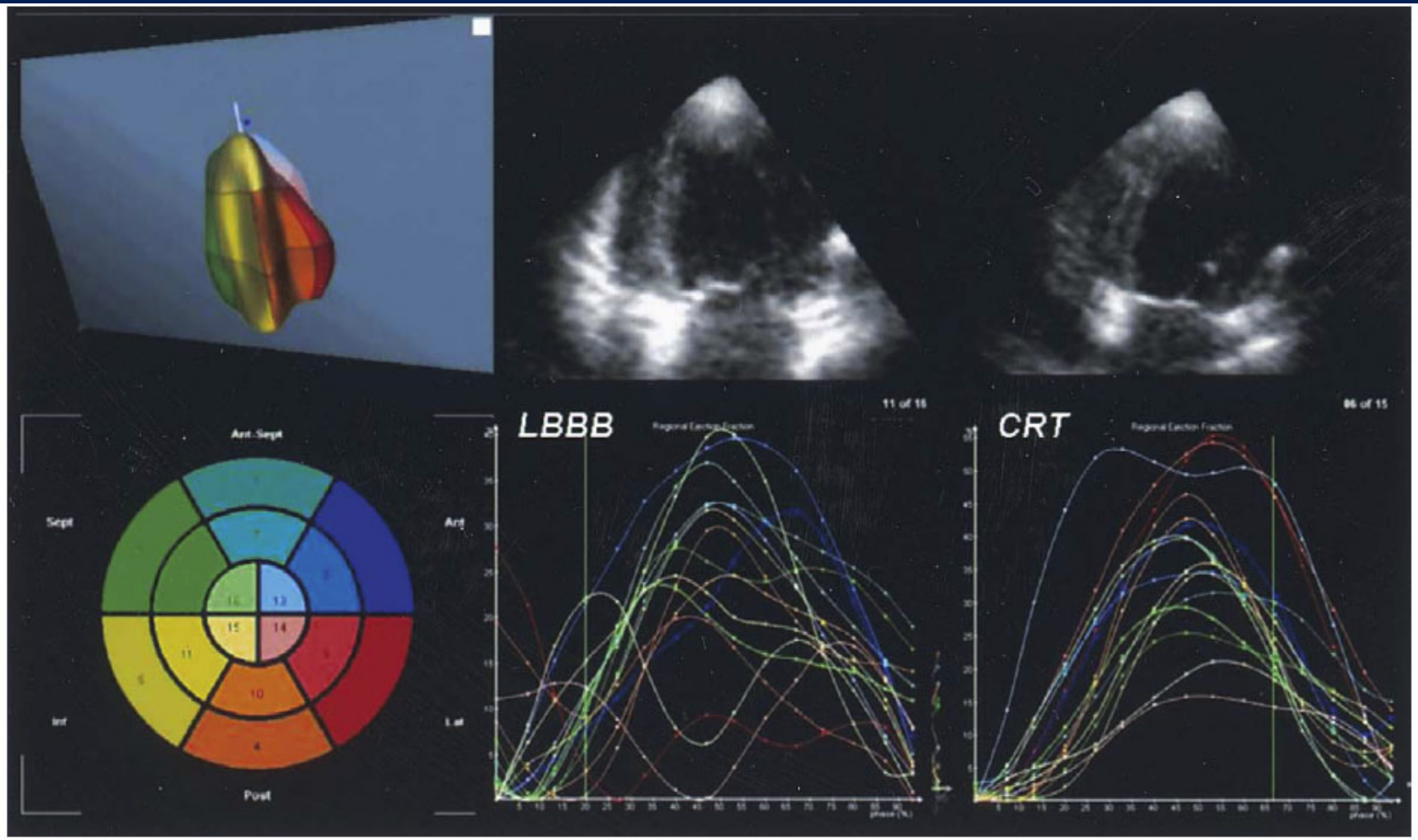


**Figure 4.** Quantification of regional wall motion from real-time three-dimensional echocardiographic data. After semiautomatic segmentation of the left ventricular chamber **(upper left)**, the extent and timing of regional wall motion is analyzed in a 16-segment model **(lower left)** and in this example expressed as regional ejection fraction over time. There is clear regional dyssynchrony between the inferoseptal and the anterolateral segments during left bundle branch block (LBBB) **(lower middle)**, which improves immediately after initiation of cardiac resynchronization therapy (CRT) **(lower right)**. (Courtesy of A. Franke, University Hospital Aachen, Germany.)

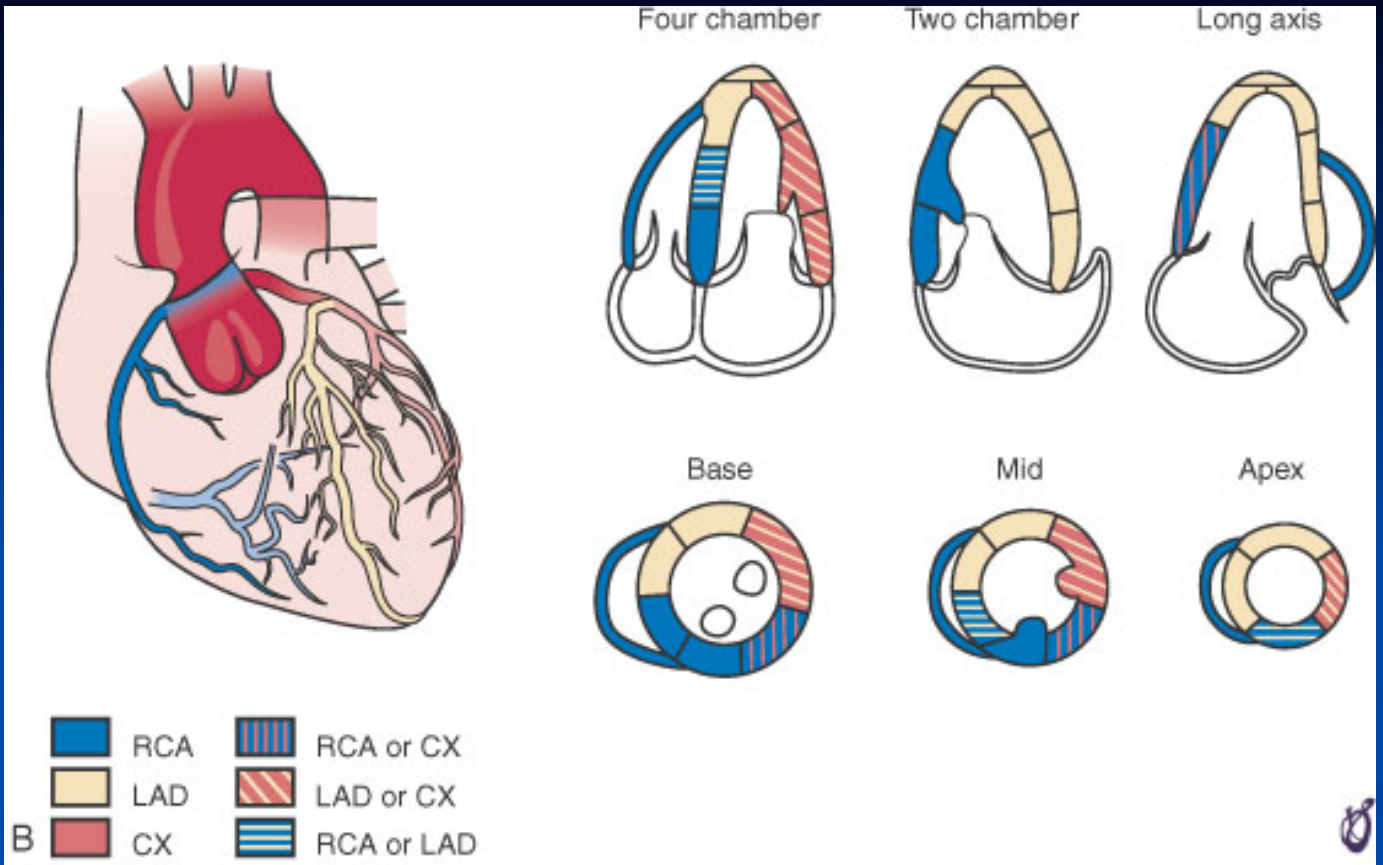


**FIGURE 14–30B A,** Diagrammatic cross sections of the left ventricle to show 17 segments for wall motion analysis. **B,** Left ventricular segments from three apical views and mid parasternal short-axis view with the corresponding coronary artery distribution.
Cx = circumflex artery; LAD = left anterior descending artery; RCA = right coronary artery.

*(Modified from Lang RM, Bierig M, Devereux RB, et al, Chamber Quantification Writing Group; American Society of Echocardiography's Guidelines and Standards Committee; European Association of Echocardiography: Recommendations for chamber quantification: A report from the American Society of Echocardiography's Guidelines and Standards Committee and the Chamber Quantification Writing Group, developed in conjunction with the European Association of Echocardiography, a branch of the European Society of Cardiology. J Am Soc Echocardiogr 18:1440, 2005. Used with permission.)*

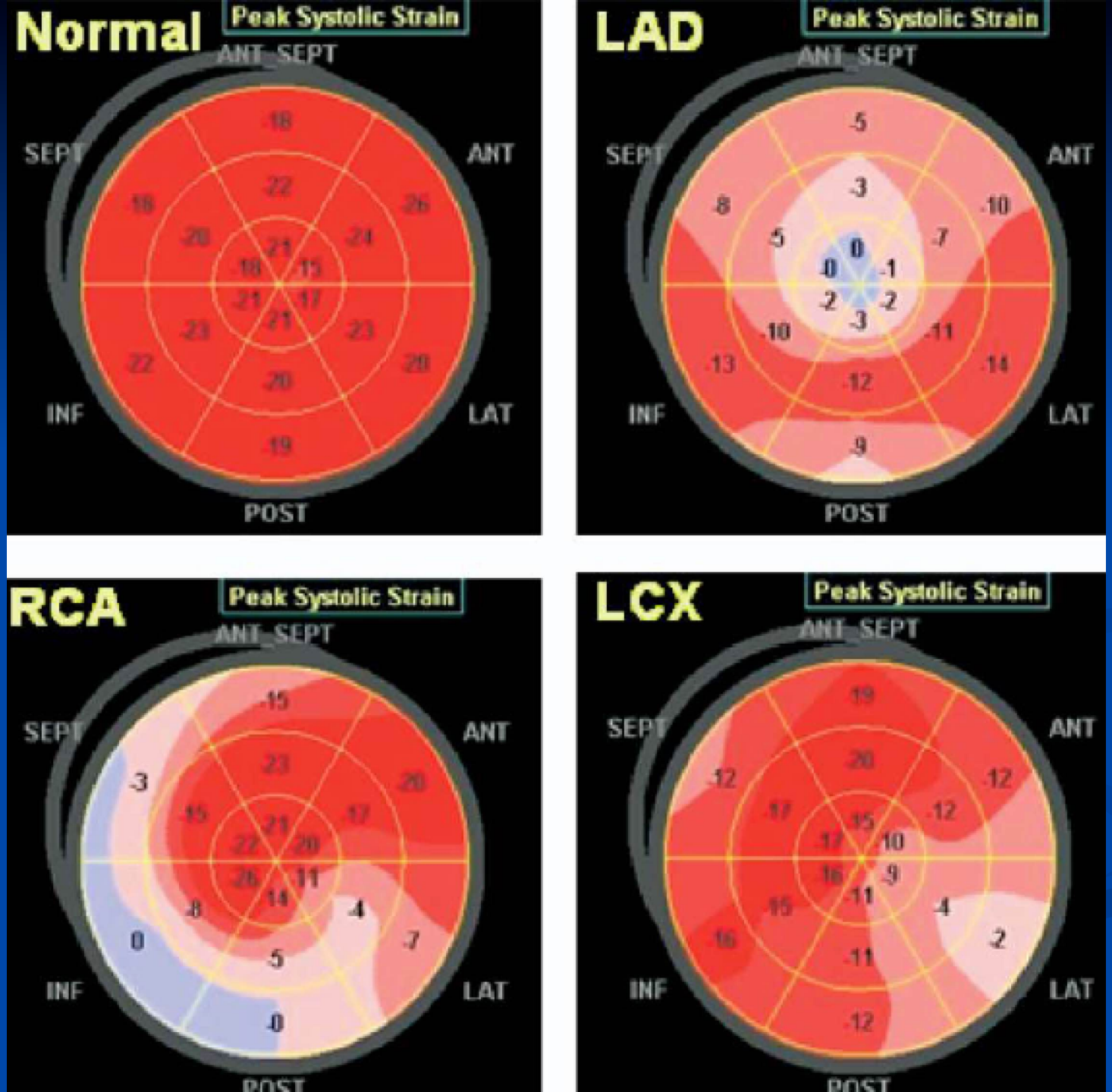
Normal
Peak Systolic Strain
ANT_SEPT
SEPT
ANT
INF
LAT
POST
LAD
Peak Systolic Strain
ANT_SEPT
SEPT
ANT
INF
LAT
POST
RCA
Peak Systolic Strain
ANT_SEPT
SEPT
ANT
INF
LAT
POST
LCX
Peak Systolic Strain
ANT_SEPT
SEPT
ANT
INF
LAT
POST

# Hibrid képalkotás
## Stress MPS + MSCT

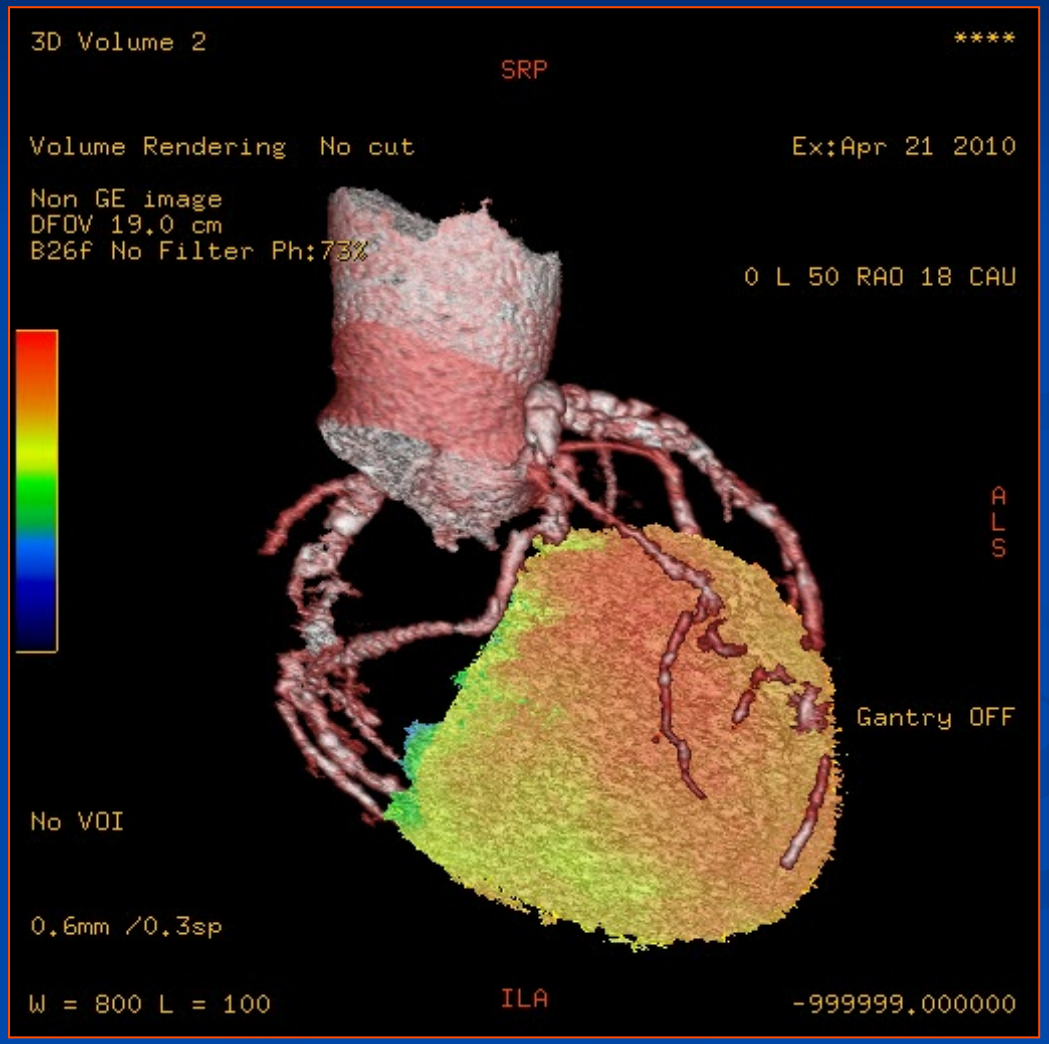

# HYPERTROPHIAS CARDIOMYOPATHIA (HCM)

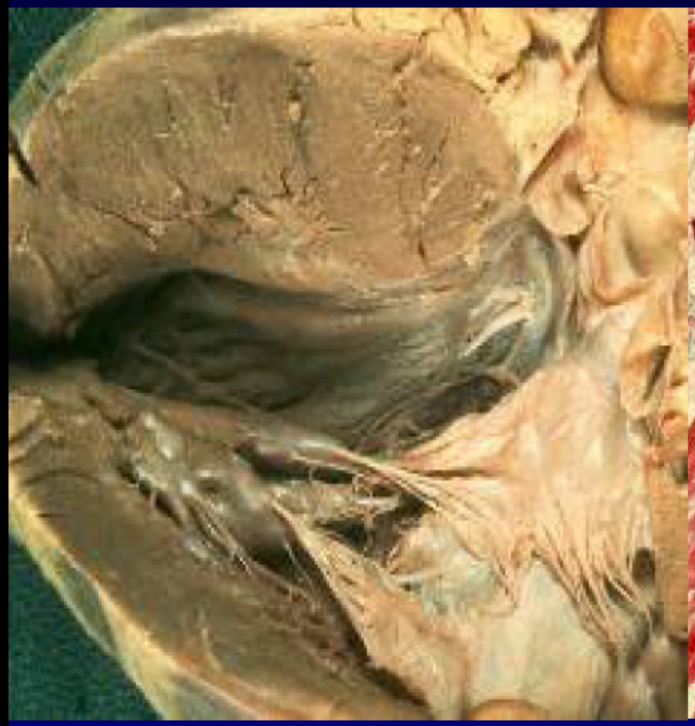

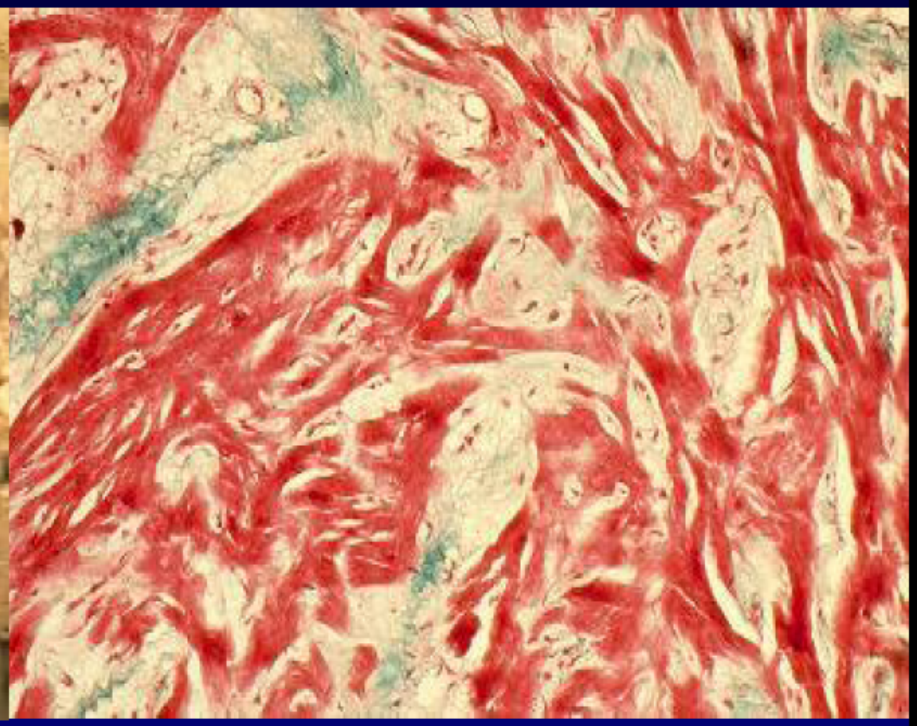

| Myocardial Hypertrophy: | Myocardial Fiber Disarray |
| --- | --- |
| Primarily septal | Interstitial Fibrosis |

Teare : Asymmetrical hypertrophy of the heart in young adults. Br Heart J 1958.

# Echo vizsgálati lehetőségek HCM-ben

- Hagyományos módszerek (2D, M-mód, Doppler)
- Szöveti Doppler, Color M-mód flow propagáció, strain, speckle tracking-BK torzió analízis, kontrasztecho, 3D echo
  - Falvastagság, izomtömeg
  - Lokalizáció
  - SAM, LVOT obstructio,
  - Szisztolés f., Diasztolés f.
  - Bal pitvar area, volume,
  - Dyssynchronia (diasztolés is!)

# Echocardiographia szerepe HCM-ben

- Hagyományos módszerek (2D, M-mód, Doppler)
- Szöveti Doppler, Color M-mód flow propagáció, strain, speckle tracking-BK torzió analízis, kontrasztecho, 3D echo
  - Falvastagság, izomtömeg
  - RV hypertrophia?, RV obstrukció?
  - LV-EF
  - LV-Diasztolés funkció
  - A. pulmonális syst. nyomás
  - Bal pitvar area, volumen, index
  - LVOT dinamikus obstrukció, SAM
  - Mitrális billentyű, papilláris izom
  - Myectomia, alkoholos abláció (TTE/TEE)

J Am Soc Echocardiogr 24, 473-98, 2011

# HCM-falvastagság

- Elsősorban septum basalis része érintett
- Egyéb lokalizáció:
  - Koncentrikus
  - Apicális
  - Lateralis fal….
  - Jobb kamra
- Falvastagság meghatározása PSAX (basalis, mid-LV, apex)
  - Maximális falvastagság
  - Hypertrophia kiterjedése
  - PLAX: túlmérés veszélye

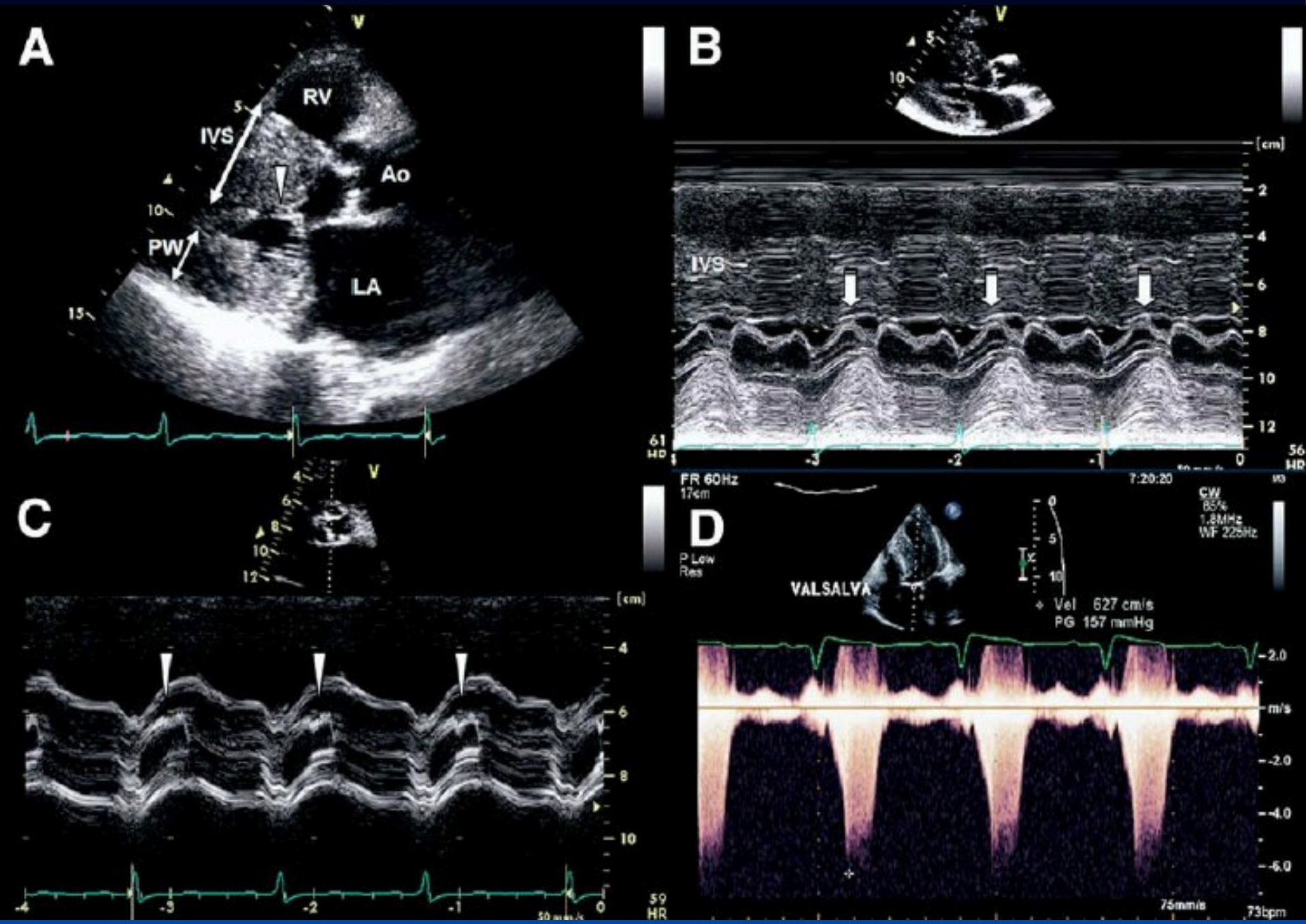
A
RV
IVS
Ao
PW
LA
B
IVS
[cm]
FR 60Hz
17cm
7:20:20
C
[cm]
D
P Low
Res
VALSALVA
CW
85%
1.8MHz
WF 225Hz
Vel 627 cm/s
PG 157 mmHg
m/s
75mm/s
73bpm

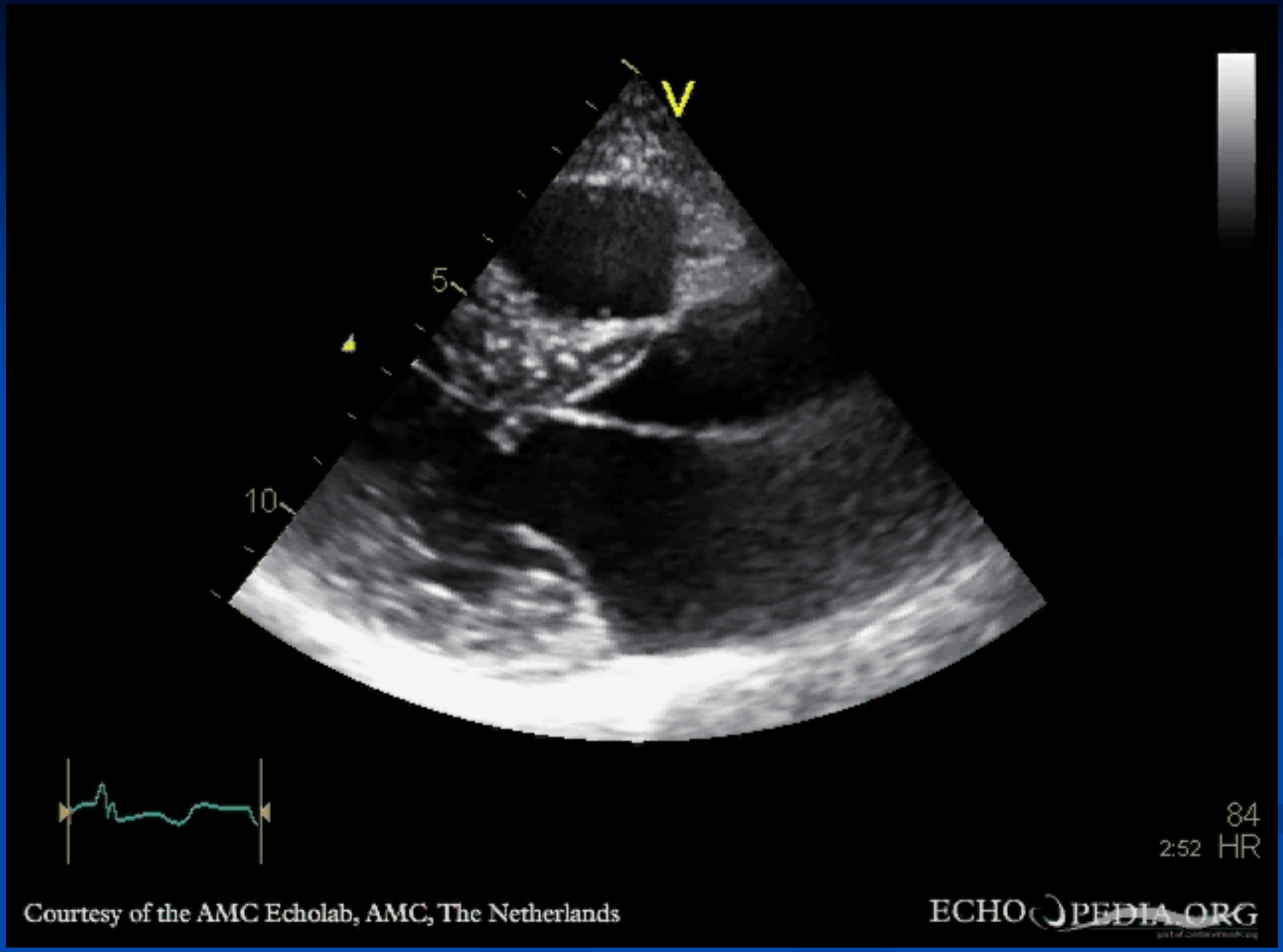
V
5
10
84
2:52 HR
Courtesy of the AMC Echolab, AMC, The Netherlands
ECHOPEDIA.ORG

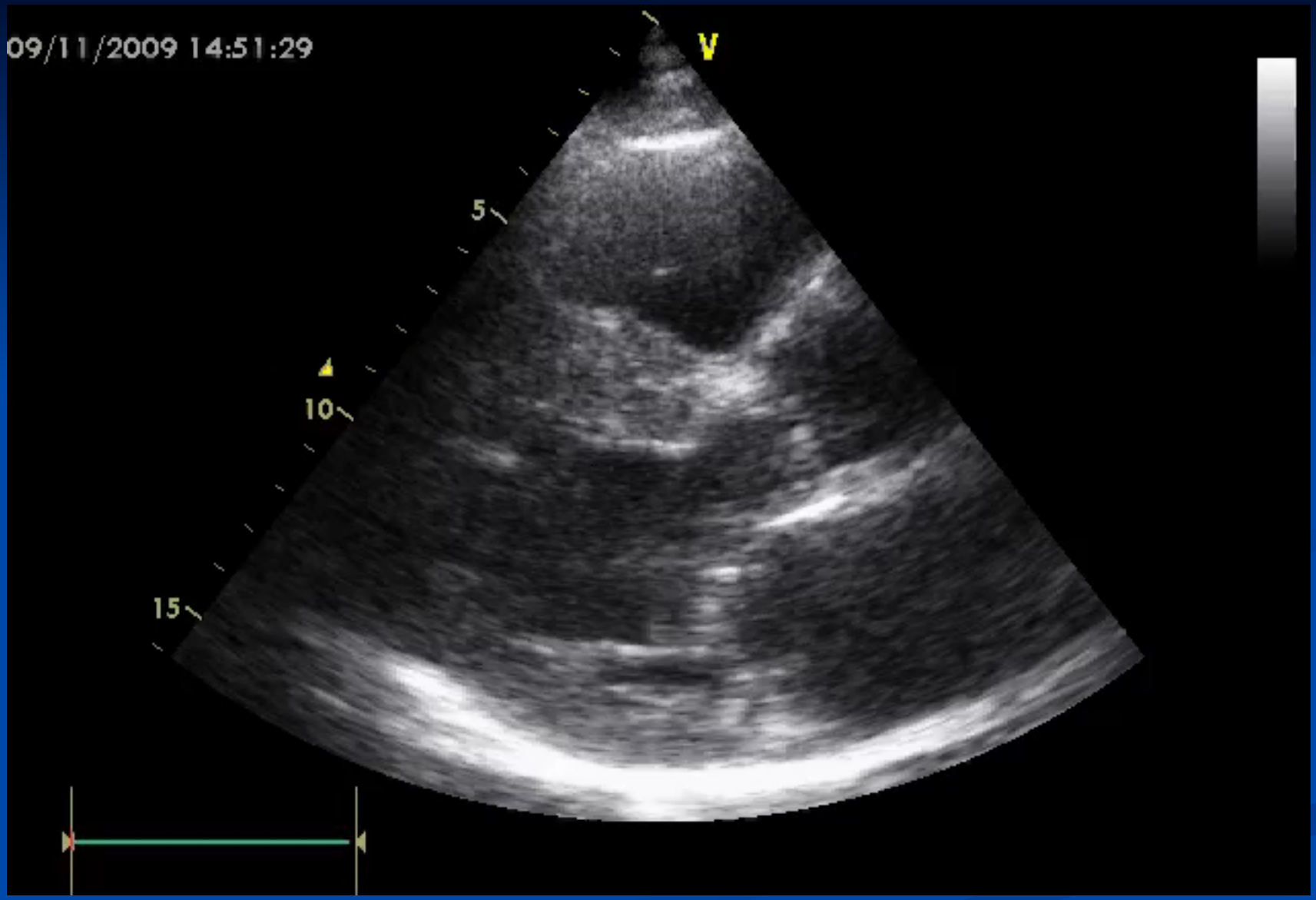
09/11/2009 14:51:29
V
5
10
15

# Mitrális mellső vitorla SAM jelensége

- SAM
  - nincs
  - nyugalmi
  - terhelésre jelentkezik csak
- Következmények
  - LVOTO (>30 Hgmm)
  - MR

# Pathophysiology of LVOT Obstruction and MR: Grigg et al JACC 1993

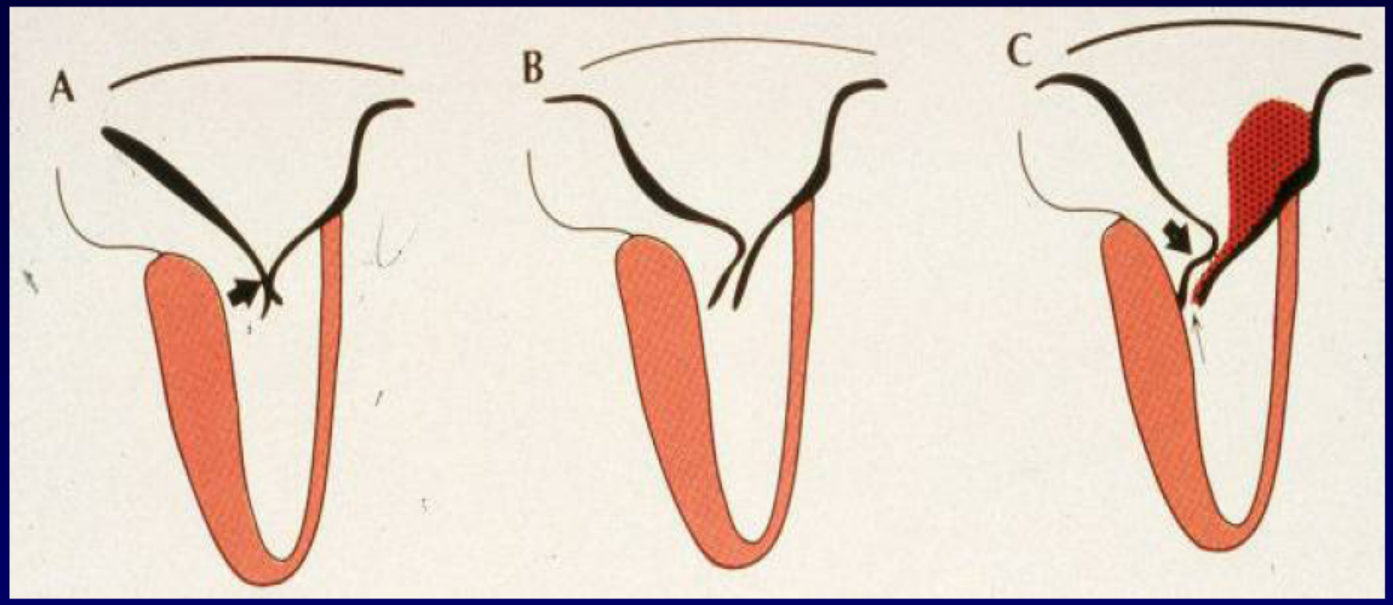


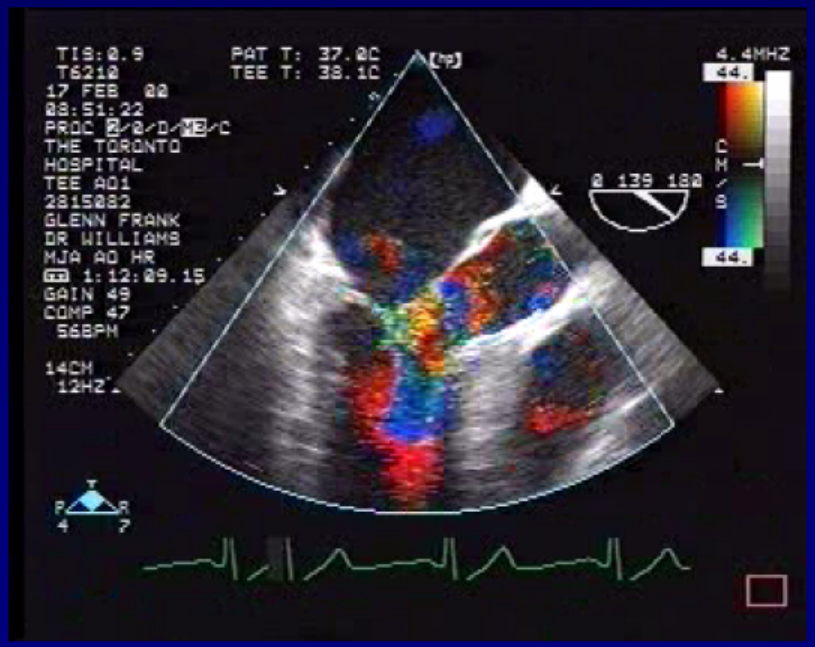


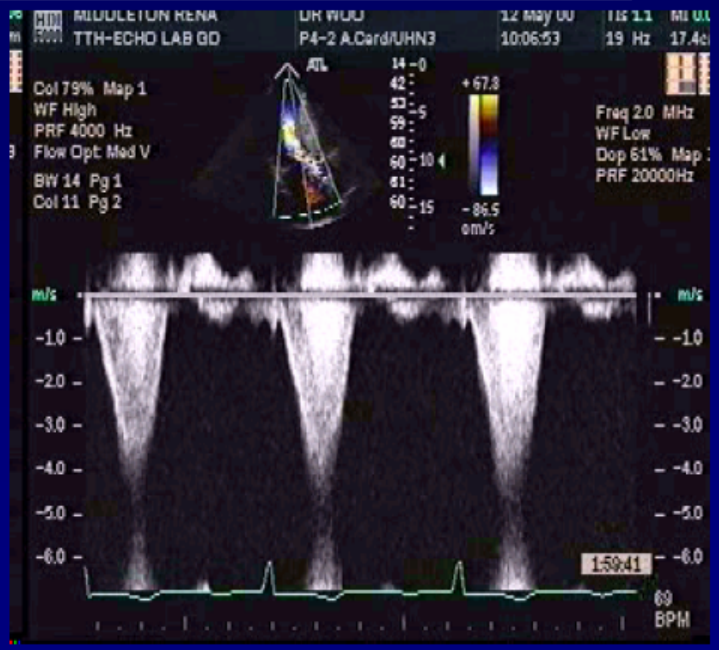

# Venturi-hatás

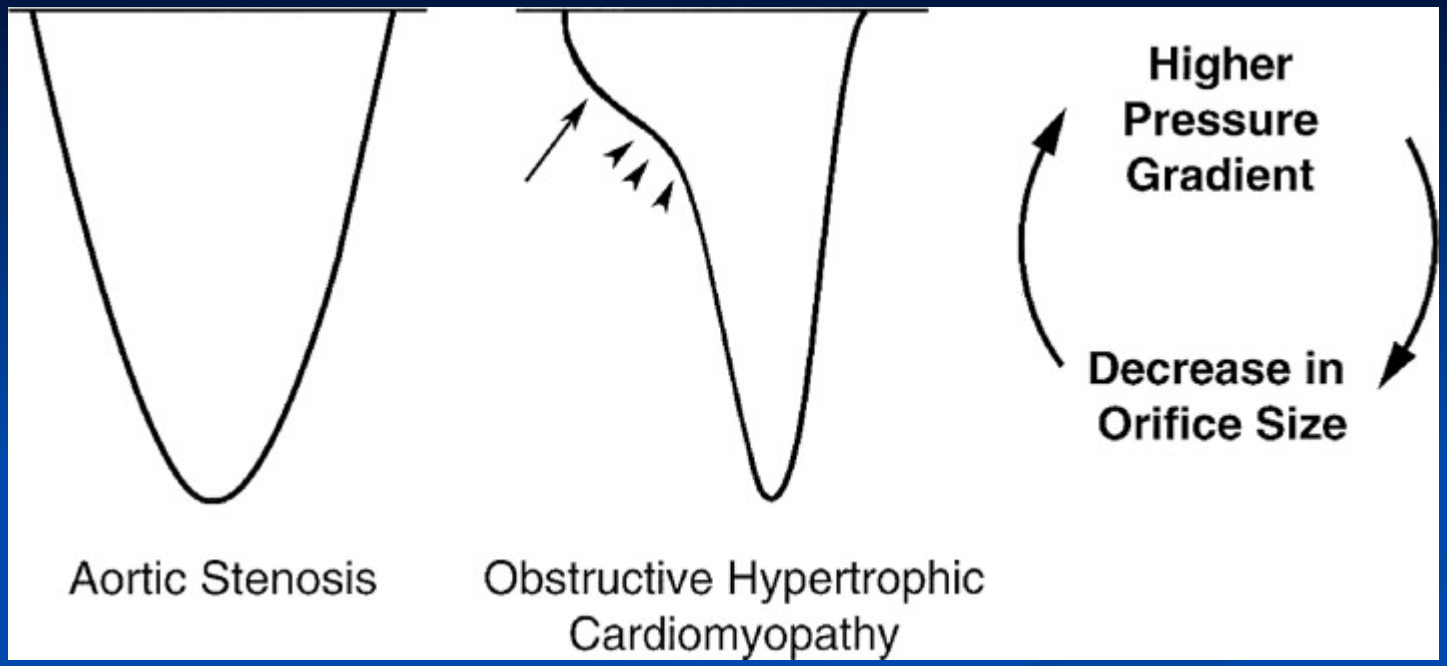
Higher
Pressure
Gradient
Decrease in
Orifice Size
Aortic Stenosis
Obstructive Hypertrophic
Cardiomyopathy

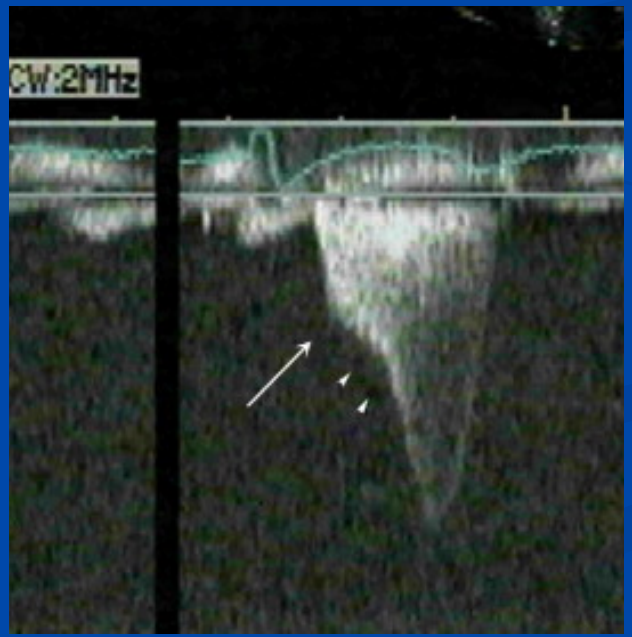
CW:2MHz

# A TDI alkalmas a pathológiás és physiologiás bal kamra hypertrophia elkülönítésére

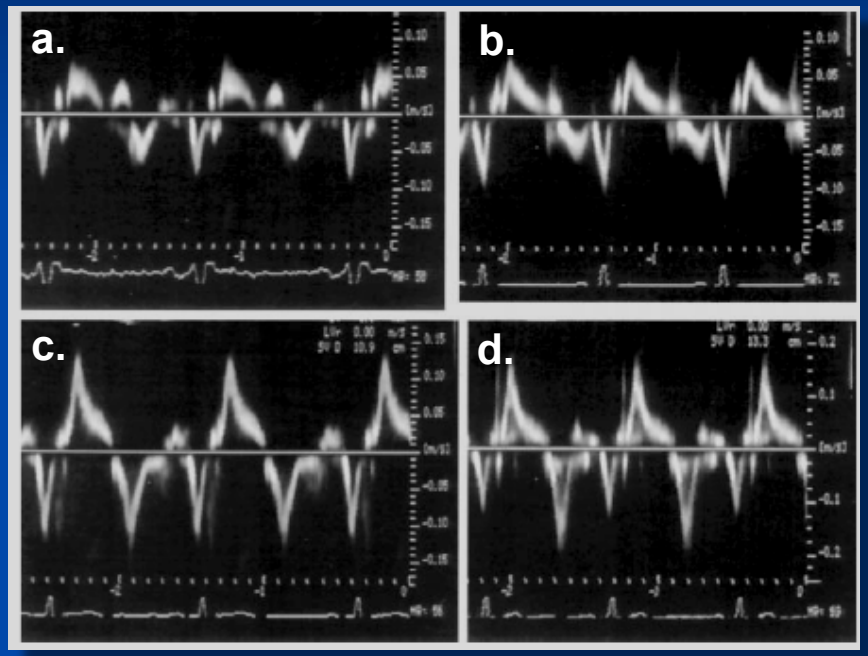


- A longitudinális funkciót nem a bal kamra hypertrophia mértéke, hanem pathológiás volta (fibrózis) befolyásolja
- HCM-ben és hypertoniás szívben S és Ea egyaránt károsodott, míg atlétákban közel normális

- Szöveti Doppler görbe a laterális anuluson mérve (a. HCM, b. hypertonia, c. egészséges személy, d. atléta)

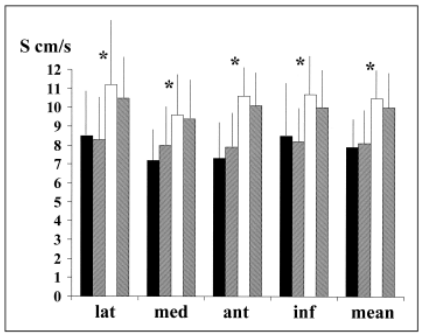


FIGURE 2. Mean ( ± SD) systolic velocities (S) of the 4 sites of the mitral annulus. ■ = HC, ▨ = systemic hypertension, □ = athletes, ▩ = normal subjects. ant = anterior; inf = inferior; lat = lateral; mean = 4-site average velocity; med = medial. *p <0.01: HC or systemic hypertension versus athletes or normal subjects.

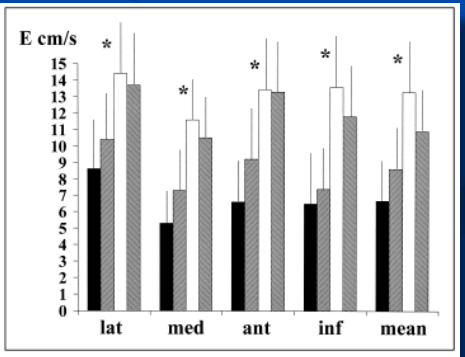


FIGURE 3. Mean ( ± SD) early diastolic velocities (E) of the 4 sites of the mitral annulus ■ = HC, ▨ = systemic hypertension, □ = athletes, ▩ = normal subjects. *p <0.01: HC or systemic hypertension versus athletes or normal subjects. Abbreviations as in Figure 2.

Vinereanu et al. Am J Cardiol 2001;88:53-58.

# Apical HCM

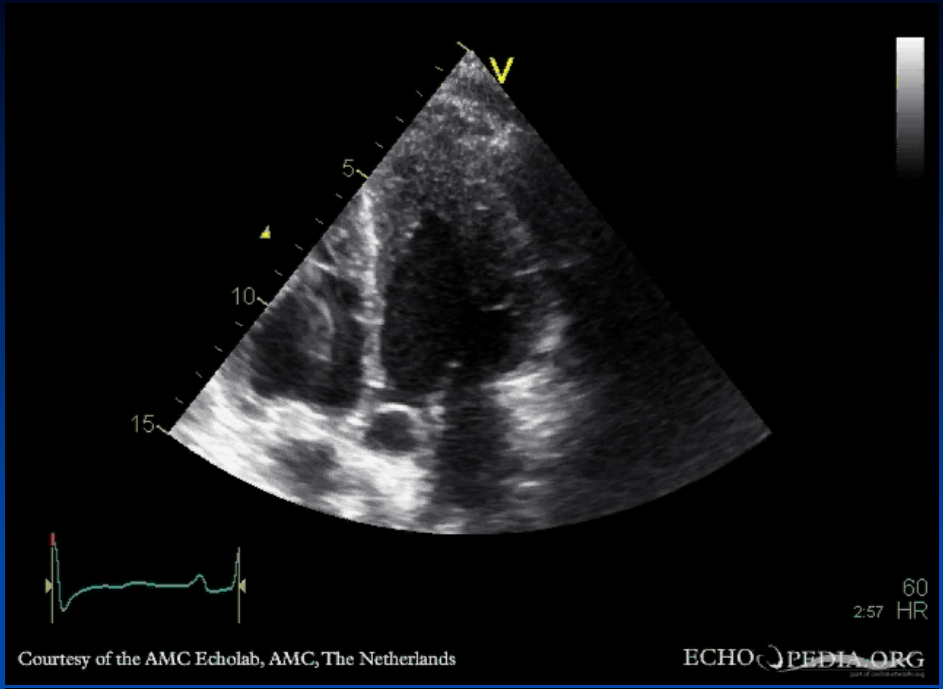
V
5
10
15
60
2:57 HR
Courtesy of the AMC Echolab, AMC, The Netherlands
ECHOPEDIA.ORG

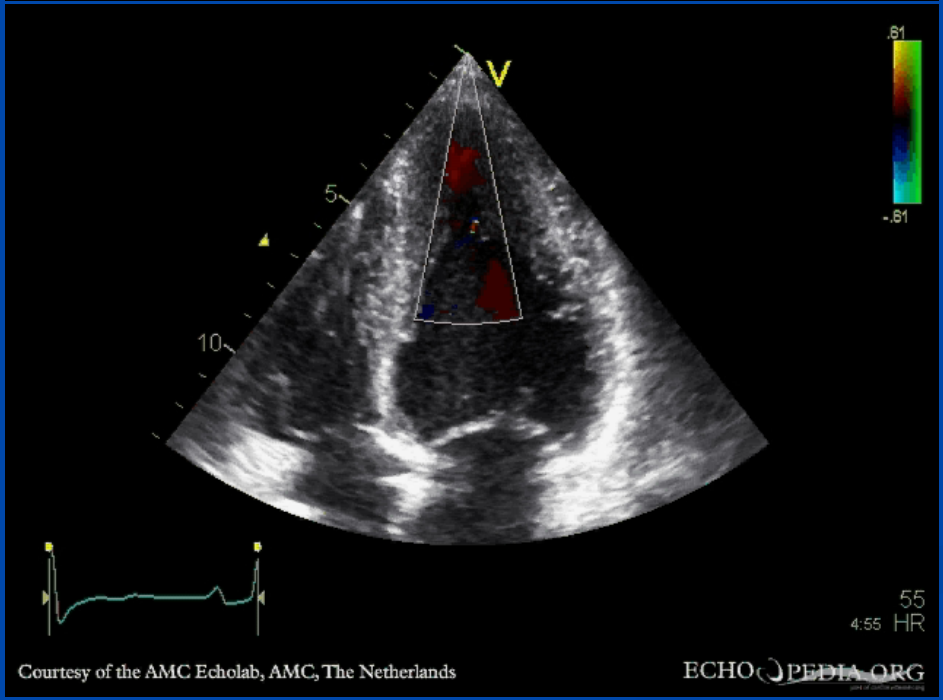
V
5
10
.61
-.61
55
4:55 HR
Courtesy of the AMC Echolab, AMC, The Netherlands
ECHOPEDIA.ORG

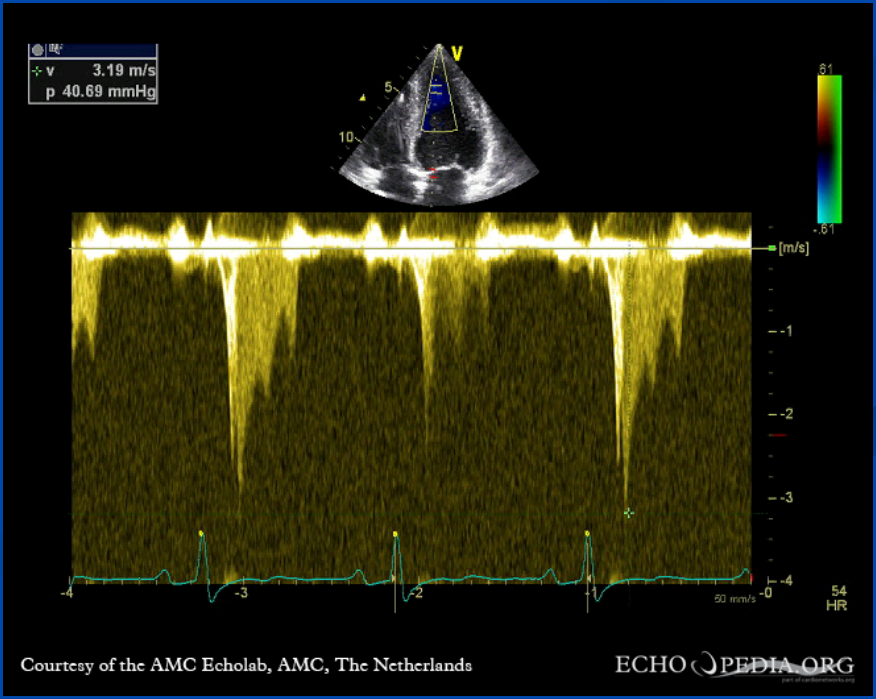
v 3.19 m/s
p 40.69 mmHg
V
5
10
.61
-.61
[m/s]
-1
-2
-3
-4
-4
-3
-2
-1
-0
50 mm/s
54
HR
Courtesy of the AMC Echolab, AMC, The Netherlands
ECHOPEDIA.ORG

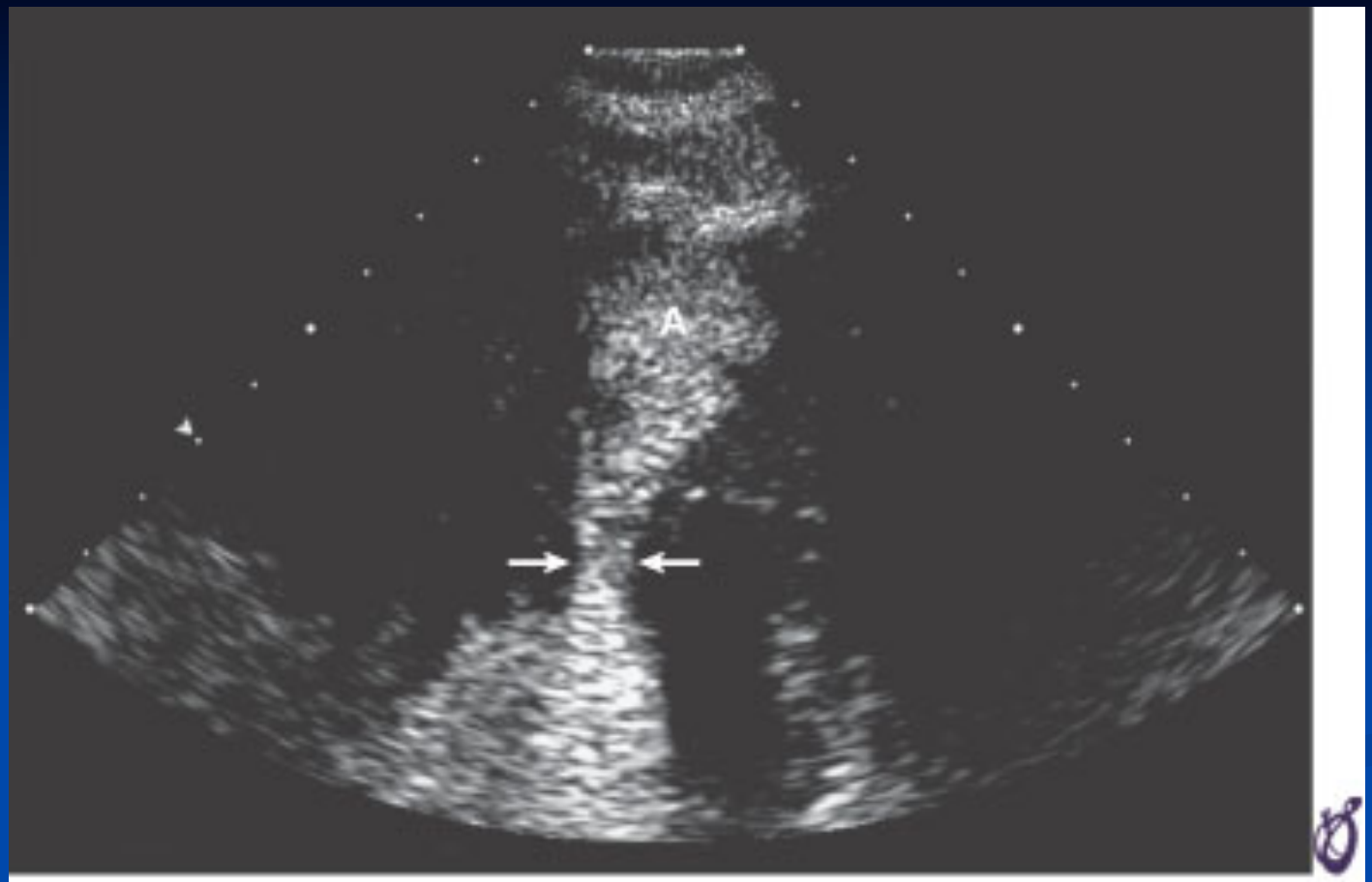


**FIGURE 14–17** Apical view showing a mid cavity obstruction (arrows) that was not visualized clearly with 2D echocardiography without contrast injection. An apical pouch (A) is clearly seen.

*(From Oh JK, Seward JB, Tajik AJ: The Echo Manual. 3rd ed. Philadelphia, Lippincott Williams & Wilkins, 2006. Used with permission of Mayo Foundation for Medical Education and Research.)*

# Intracoronary myocardial contrast echocardiography in the harmonic imaging mode demonstrated that the patient was unsuitable for alcohol septal ablation.

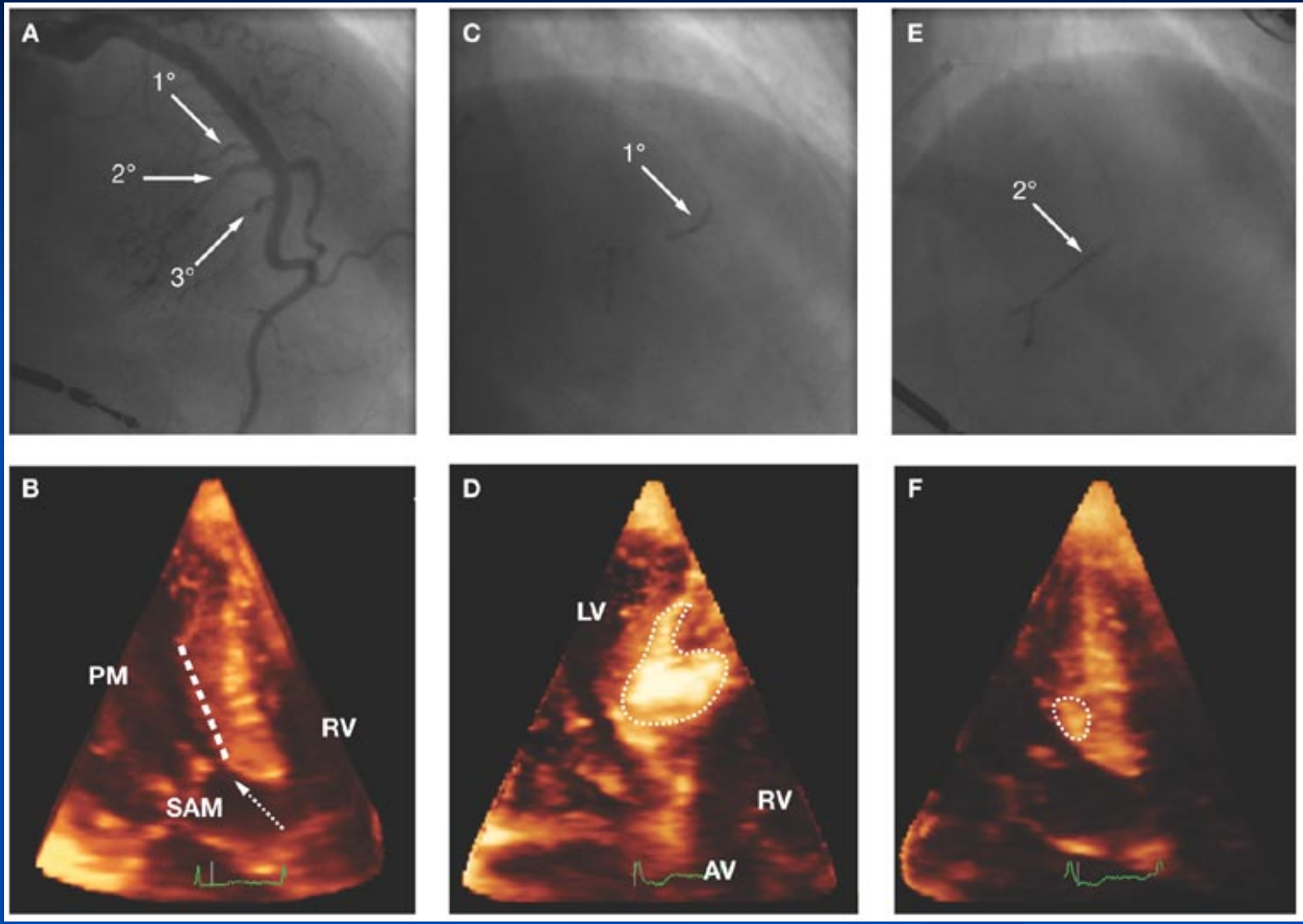


La Canna G *et al.* (2007) Alcohol septal ablation versus surgical myectomy:a patient with obstructive HCM
*Nat Clin Pract Cardiovasc Med* **4:** 570–576 doi:10.1038/ncpcardio0988

nature CLINICAL PRACTICE CARDIOVASCULAR MEDICINE

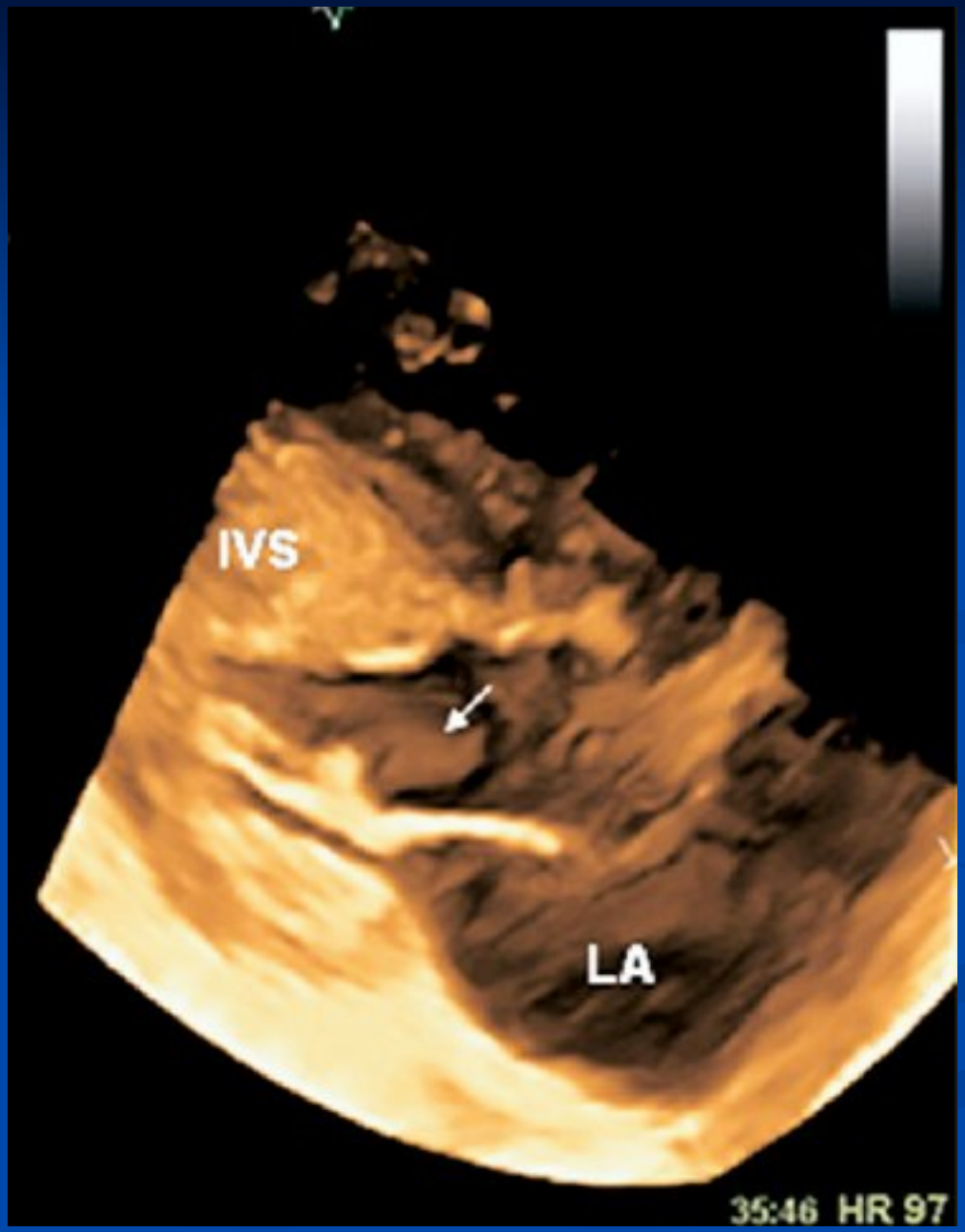
IVS
LA
35:46 HR 97


# 1-HCM is a disease of many faces

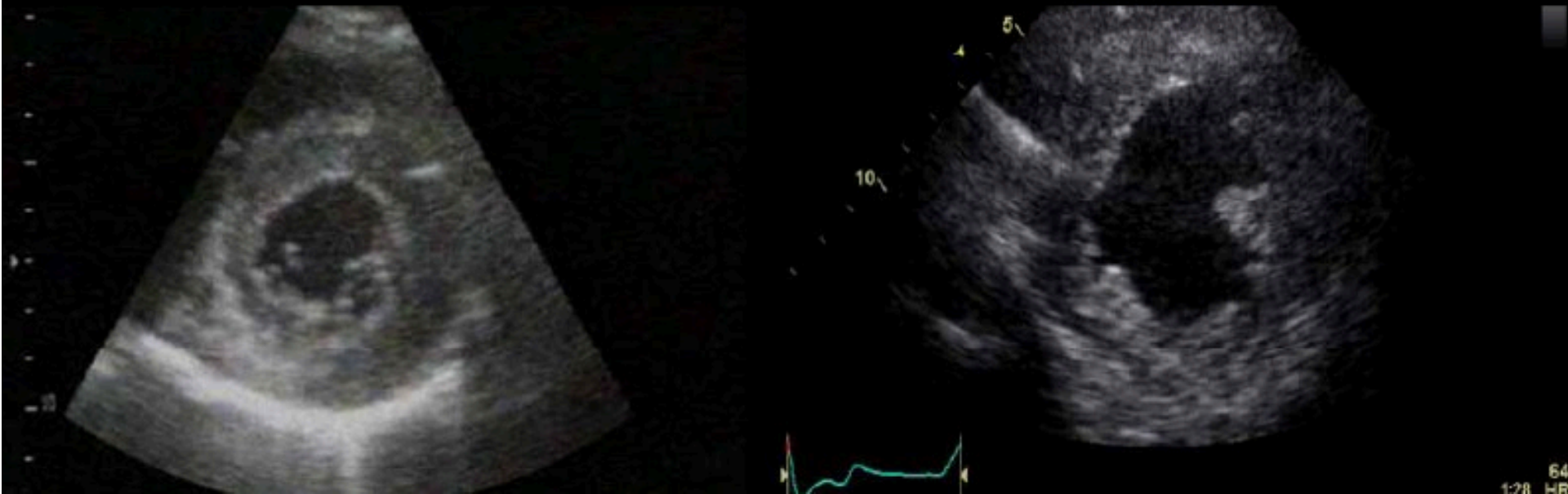

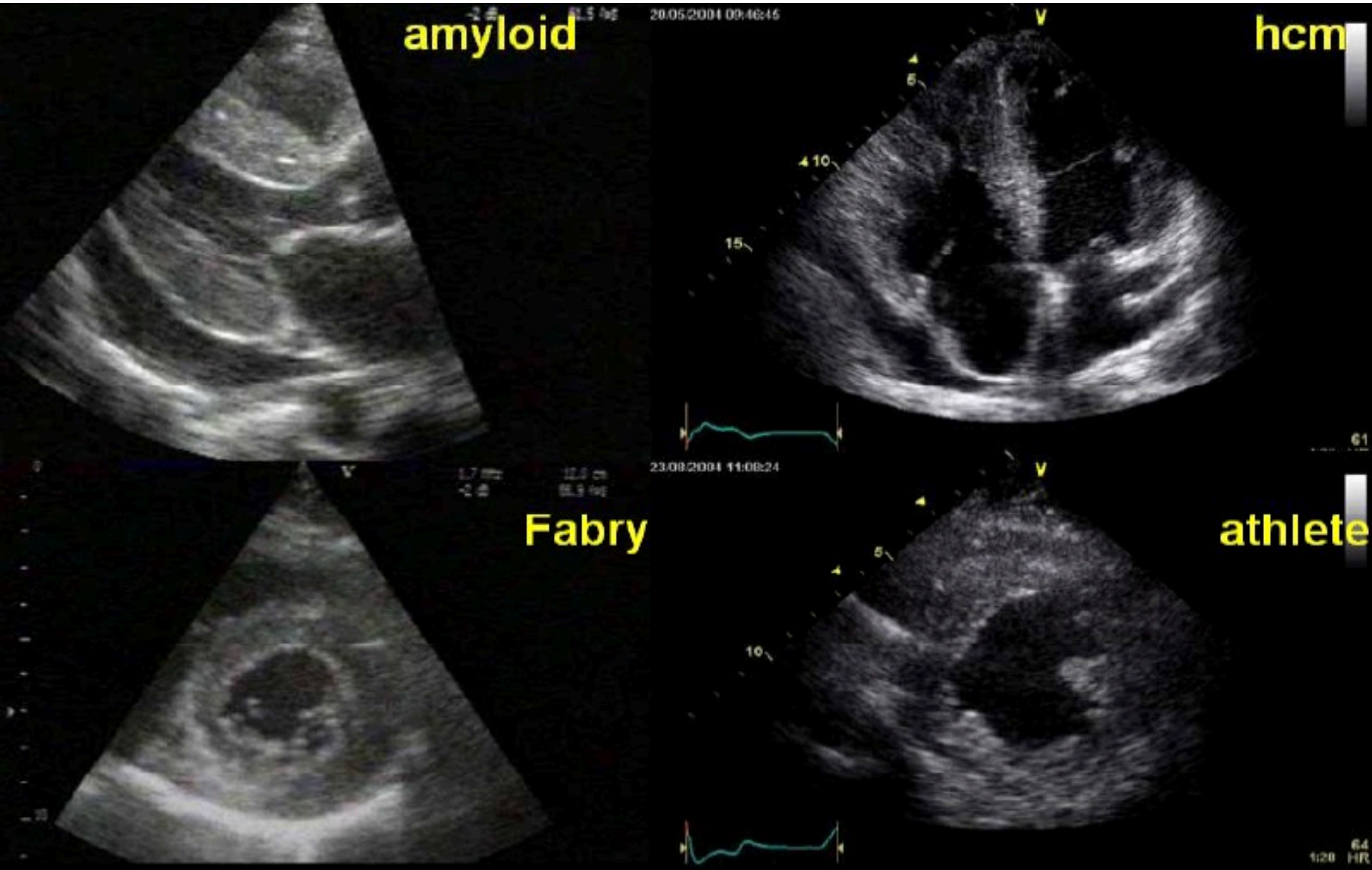


2-The presence of LVH is not the end, but the begining of the story

3- The correct diagnosis is important in theraphy & prognosis

**Table 5** Echocardiographic features that suggest specific aetiologies (modified from Rapezzi et al.[67])

| Finding | Specific diseases to be considered |
|---|---|
| Increased interatrial septum thickness | Amyloidosis |
| Increased AV valve thickness | Amyloidosis; Anderson-Fabry disease |
| Increased RV free wall thickness | Amyloidosis, myocarditis, Anderson-Fabry disease, Noonan syndrome and related disorders |
| Mild to moderate pericardial effusion | Amyloidosis, myocarditis |
| Ground-glass appearance of ventricular myocardium on 2D echocardiography | Amyloidosis |
| Concentric LVH | Glycogen storage disease, Anderson-Fabry disease, PRKAG2 mutations |
| Extreme concentric LVH (wall thickness ≥30 mm) | Danon disease, Pompe disease |
| Global LV hypokinesia (with or without LV dilatation) | Mitochondrial disease, TTR-related amyloidosis, PRKAG2 mutations, Danon disease, myocarditis, advanced sarcomeric HCM, Anderson-Fabry disease |
| Right ventricular outflow tract obstruction | Noonan syndrome and associated disorders |

2014 ESC Guidelines on diagnosis and management of hypertrophic cardiomyopathy: the Task Force for the Diagnosis and Management of Hypertrophic Cardiomyopathy of the European Society of Cardiology (ESC). Eur Heart J. 35(39), 2733-79, 2014.

# 2D 3D AND 3LAYER STE HCM

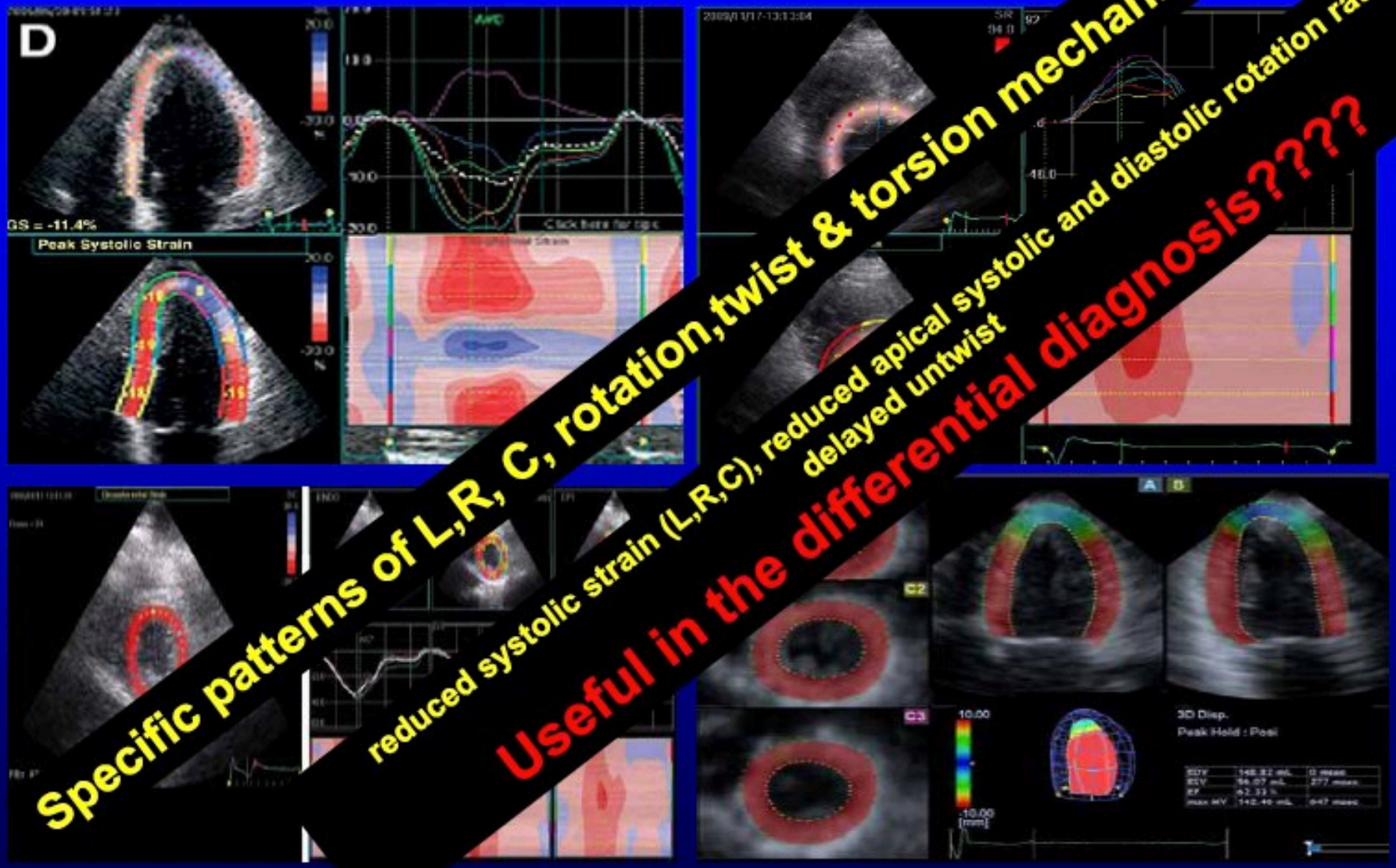


Specific patterns of L,R, C, rotation,twist & torsion mechanics

reduced systolic strain (L,R,C), reduced apical systolic and diastolic rotation rates, delayed untwist

Useful in the differential diagnosis????

Abozguia Am Heart J 2010

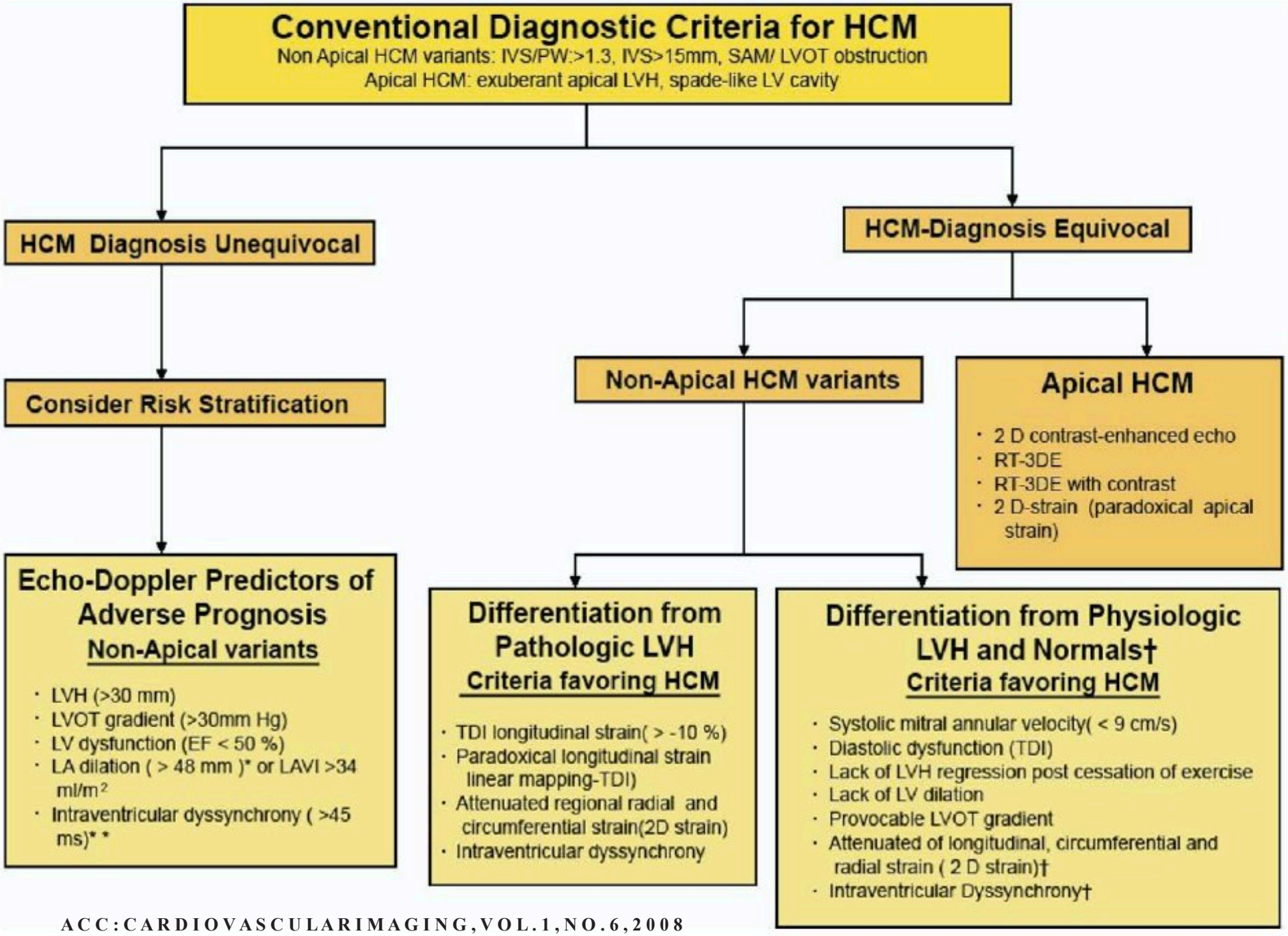
Conventional Diagnostic Criteria for HCM
Non Apical HCM variants: IVS/PW:>1.3, IVS>15mm, SAM/ LVOT obstruction
Apical HCM: exuberant apical LVH, spade-like LV cavity
HCM Diagnosis Unequivocal
HCM-Diagnosis Equivocal
Consider Risk Stratification
Non-Apical HCM variants
Apical HCM
· 2 D contrast-enhanced echo
· RT-3DE
· RT-3DE with contrast
· 2 D-strain (paradoxical apical strain)
Echo-Doppler Predictors of Adverse Prognosis
Non-Apical variants
· LVH (>30 mm)
· LVOT gradient (>30mm Hg)
· LV dysfunction (EF < 50 %)
· LA dilation ( > 48 mm )* or LAVI >34 ml/m2
· Intraventricular dyssynchrony ( >45 ms)* *
Differentiation from Pathologic LVH
Criteria favoring HCM
· TDI longitudinal strain( > -10 %)
· Paradoxical longitudinal strain linear mapping-TDI)
· Attenuated regional radial and circumferential strain(2D strain)
· Intraventricular dyssynchrony
Differentiation from Physiologic LVH and Normals†
Criteria favoring HCM
· Systolic mitral annular velocity( < 9 cm/s)
· Diastolic dysfunction (TDI)
· Lack of LVH regression post cessation of exercise
· Lack of LV dilation
· Provocable LVOT gradient
· Attenuated of longitudinal, circumferential and radial strain ( 2 D strain)†
· Intraventricular Dyssynchrony†

# RCM - OSZTÁLYOZÁS

***MYOCARDIALIS***

- Noninfiltratív - idiopathiás, scleroderma, diabetes
- Infiltratív - amiloid, sarcoid, Gaucher kór
- Tárolási betegségek - haemochromatosis, Fabry kór, stb.

***ENDOMYOCARDIALIS***

- Endomyocardialis fibrosis (EMF)
- Hypereosinophil syndroma (HES)
- Carcinoid
- Metastaticus malignómák
- Irradiáció
- Anthtracycline toxicitás

# RCM echocardiographiás jellemzői

- Kisebb vagy normális balkamrai üregméretek
- Balkamra hypertrophia nincs/enyhe
- Igen tág pitvarok, tág IVC
- Jó/enyhén csökkent systoles BKF
- Súlyos diasztoles funkciózavar

# Amyloid szív

- ECHO-val vastag falak, csillámlás; EKG-n low voltage

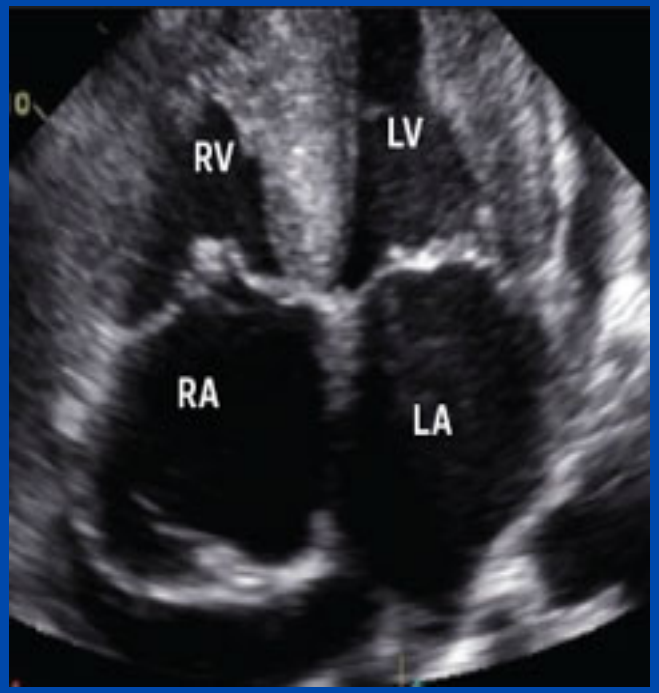


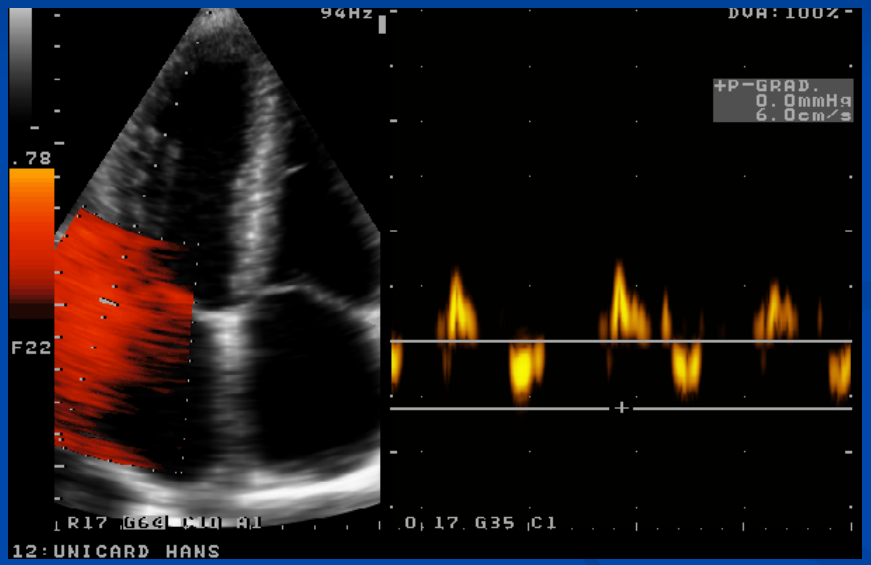


- Károsodott systolés és diasztolés longitudinális funkció

# Amyloid szív

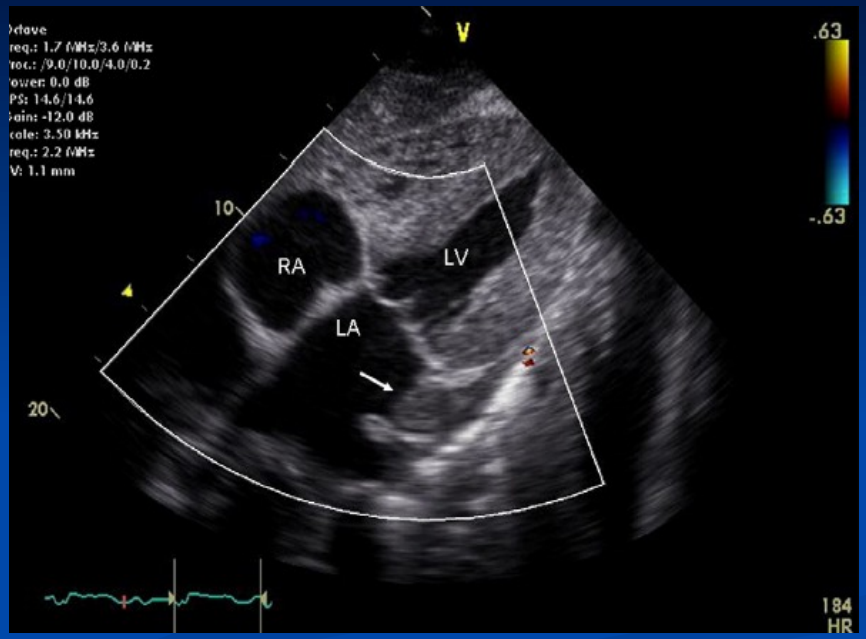


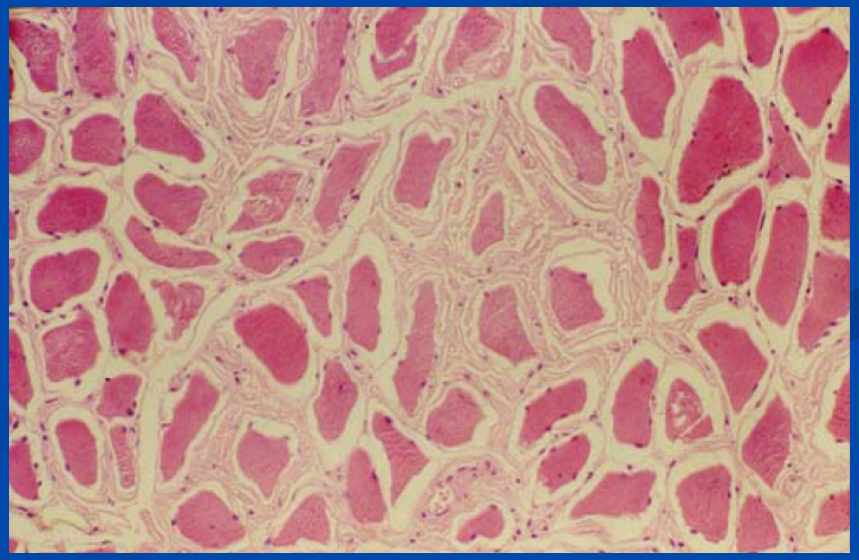

## Amyloid Heart Disease – Echo Features

- Ground glass pattern
- Left ventricular hypertrophy
- Atrial enlargement
- Thickened interatrial septum
- Thickened valves frequently with mild regurgitations
- Advanced diastolic dysfunction
- Pericardial/Pleural effusion
- "Apical sparing pattern" of longitudinal strain
- Systolic dysfunction (endstage)
- Right heart involvement

The echocardiogram is often so typical that it leads to the diagnosis of amyloidosis.

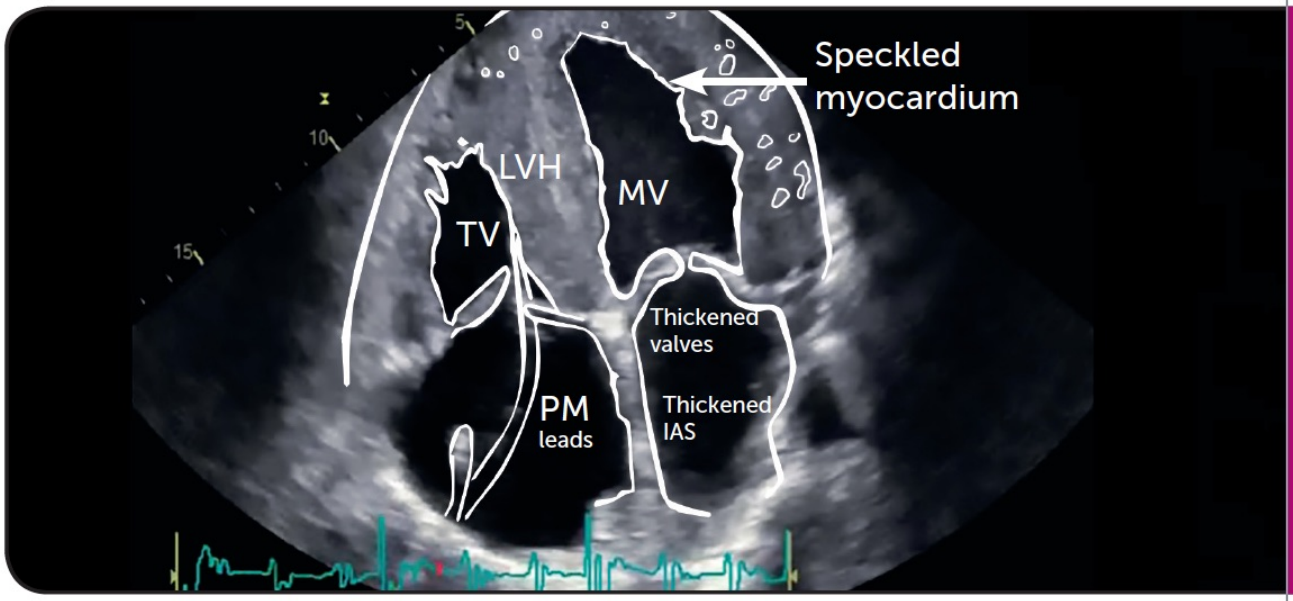


AMYLOIDOSIS – apical four-chamber view/2D

Typical features of amyloidosis, including echogenic/hourglass appearance of the myocardium, thickened valves, and enlarged atria. This patient also received a pacemaker.

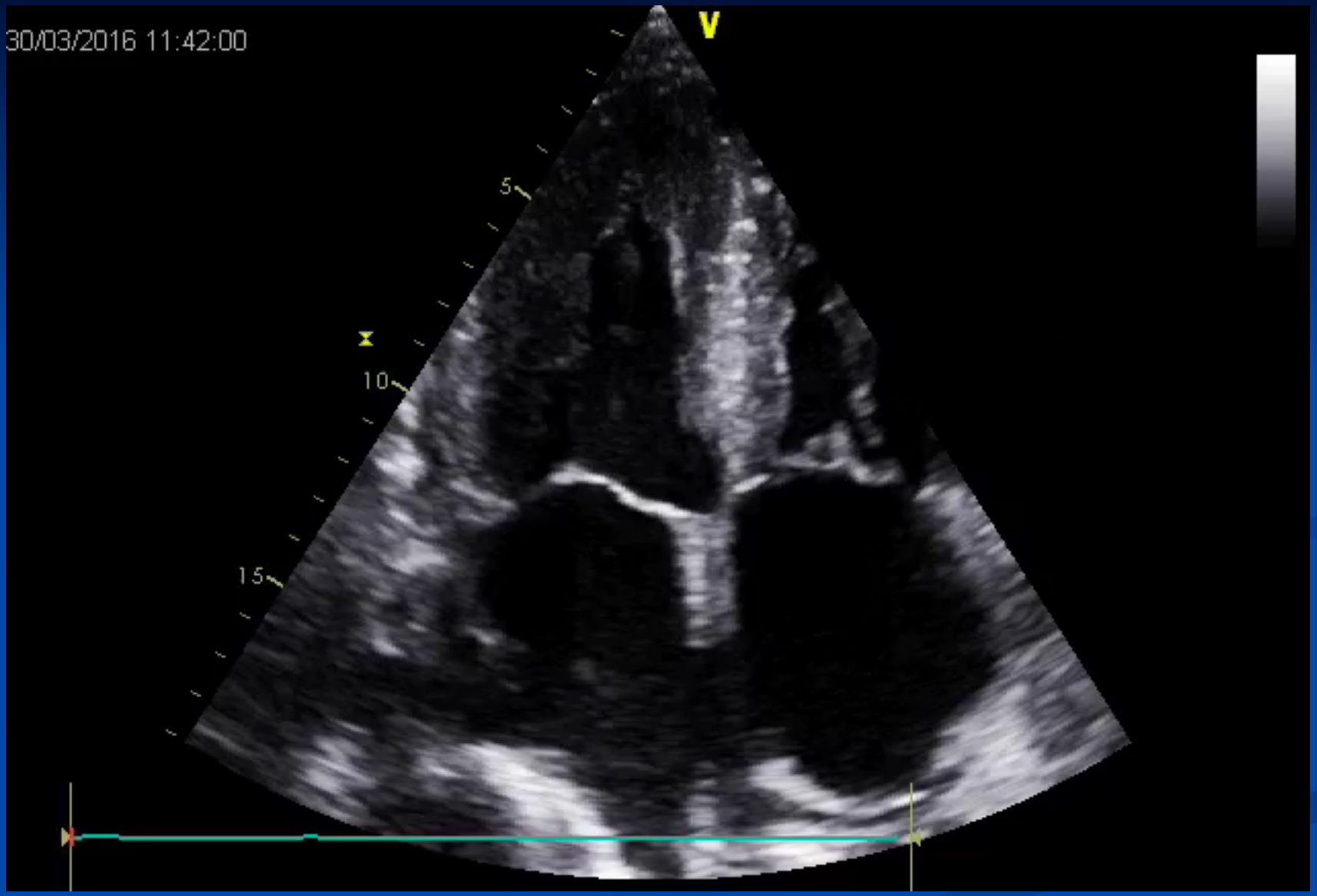
30/03/2016 11:42:00
V
5
10
15

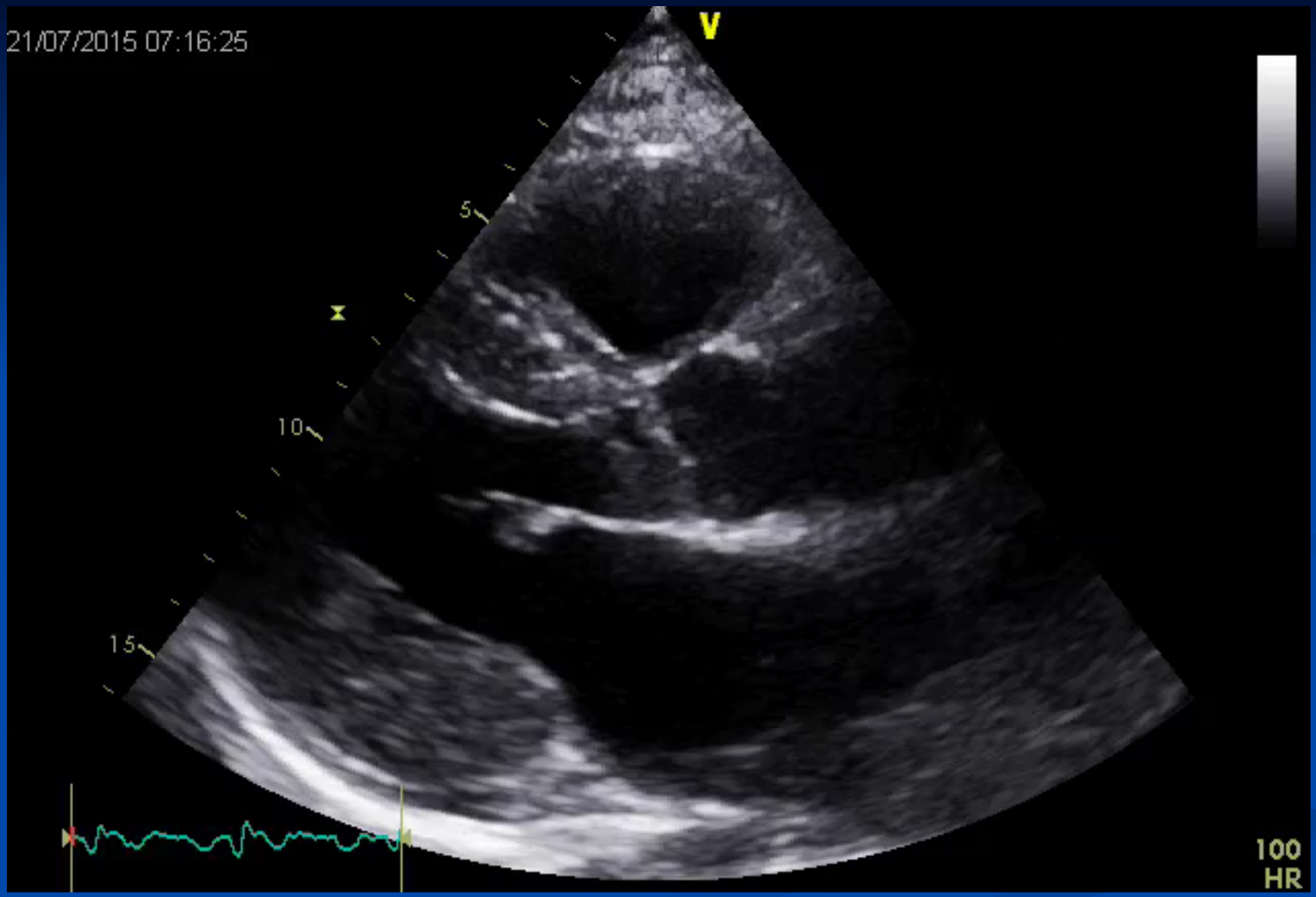
21/07/2015 07:16:25
V
5
10
15
100
HR

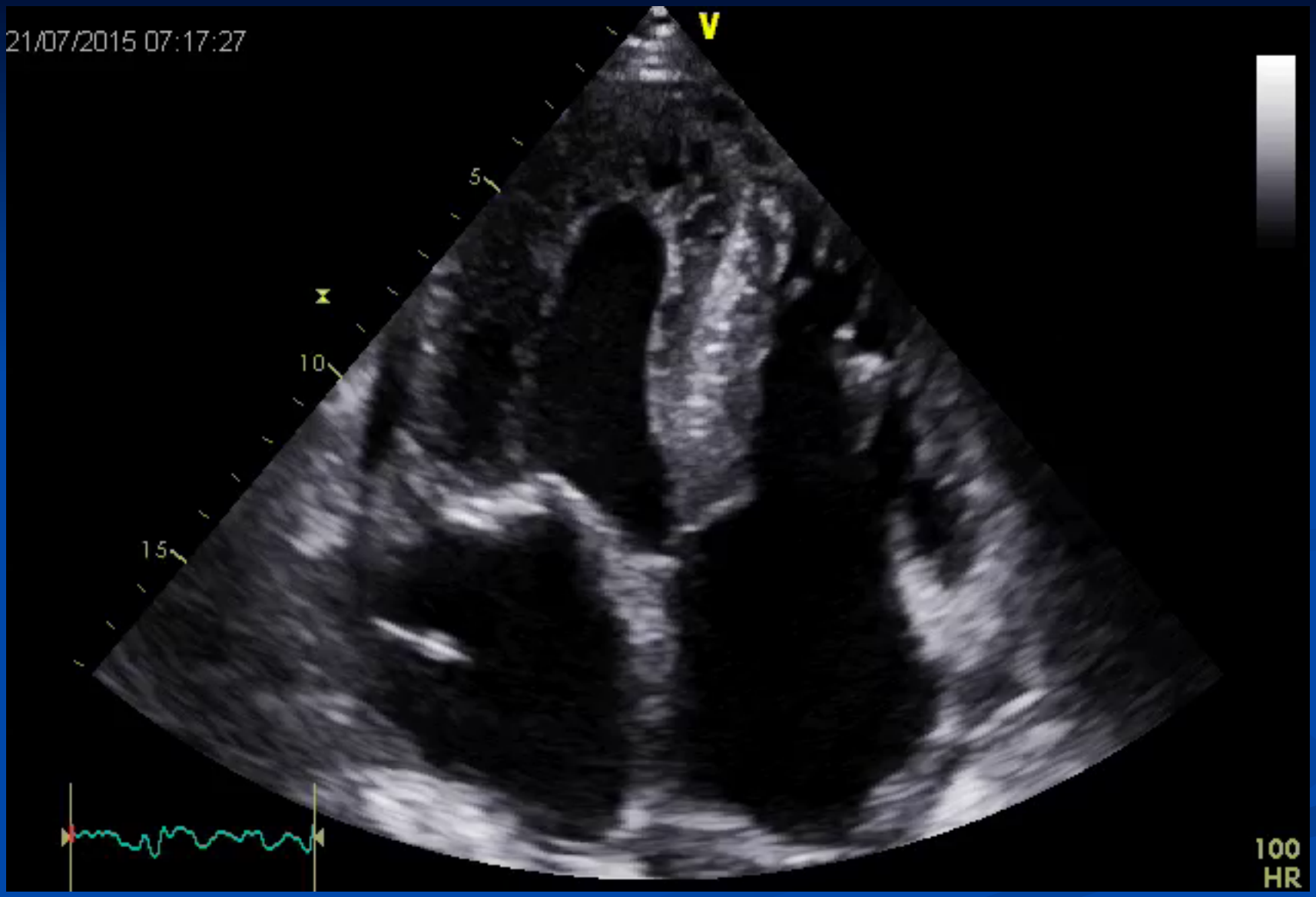
21/07/2015 07:17:27
V
5
10
15
100
HR

# Endomyocardiális Fibrosis

Endemic in parts of Africa, India, South and Central America, Asia
15-25% of cardiac deaths in equatorial Africa
hypereosinophilic syndrome (Loffler's endocarditis)

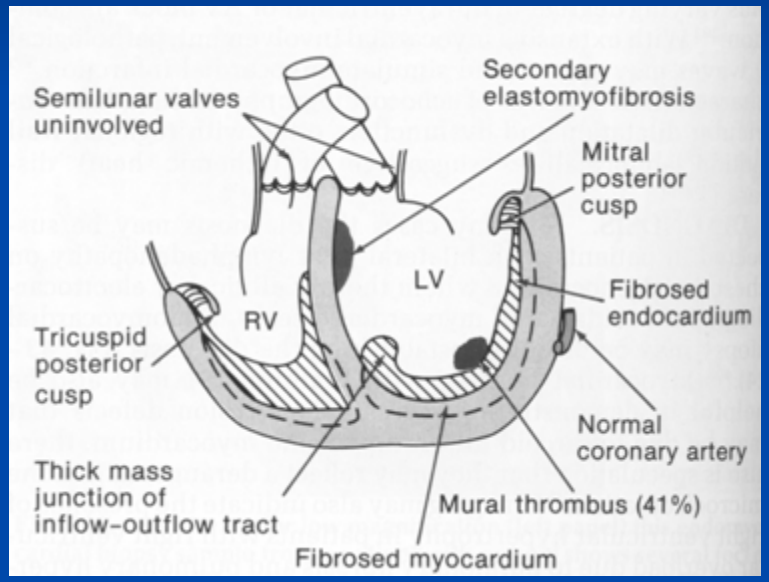


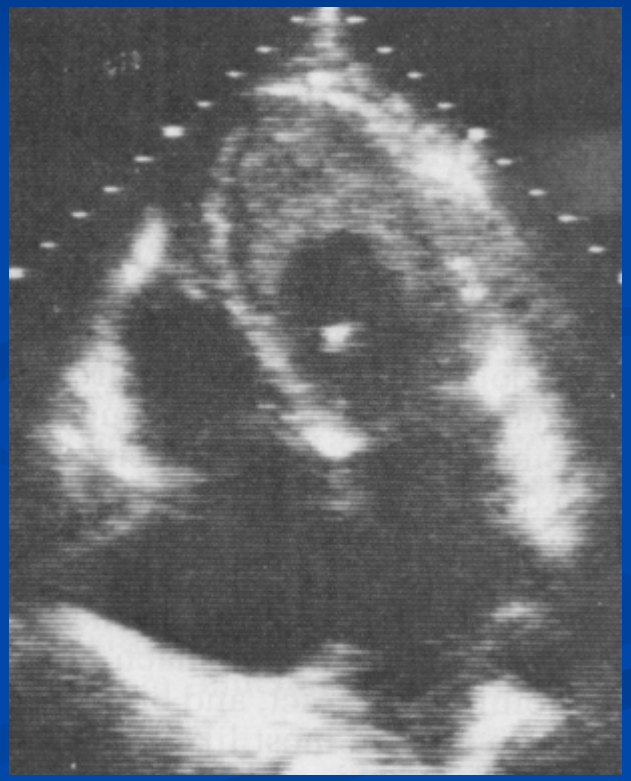

Thickening of basal inferior wall
endocardial deposition of thrombus
apical obliteration
mitral regurgitation
80-90% die within 1-2 years

Some authors suggest that the binary sign, defined as binary appearance of the left ventricular endocardial border, aids in the diagnosis of Fabry's disease. However, the sensitivity and specificity of this sign is rather low.

## Fabry's Disease: Echo Features

- Left ventricular hypertrophy
- Right ventricular hypertrophy
- Myocardial fibrosis
- Diastolic dysfunction/enlarged left atria

FABRY'S DISEASE – apical four-chamber view/2D

Pronounced bi-ventricular hypertrophy and rather speckled appearance of the myocardium.

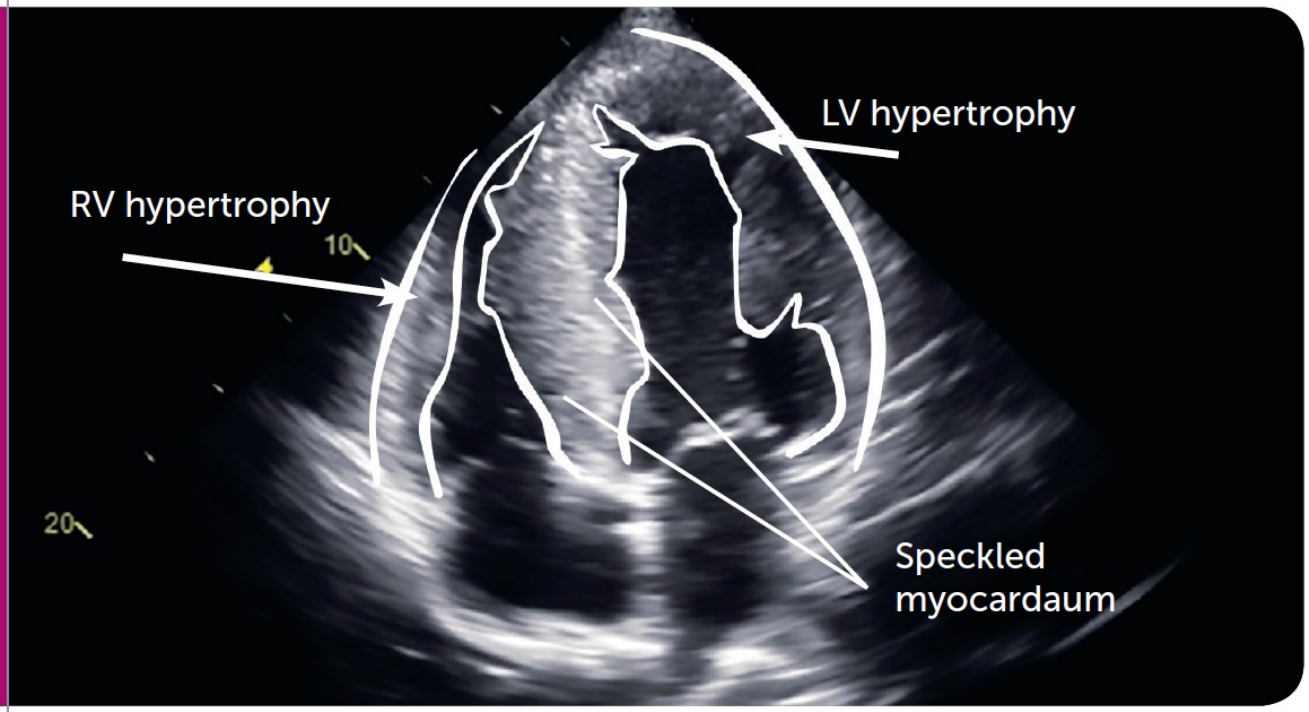

## Sarcoid Heart Disease – Echo Features

- Cardiac involvement in sarcoidosis is associated with a poor prognosis
- Pericardial effusion
- Left ventricular aneurysms
- Wall motion abnormalities (not related to coronary perfusion territories)
- Hypertrophy (segmental)
- Edema/Fibrosis
- End-stage: left ventricular dilatation, wall thinning and impaired left ventricular function

20 – 30 % of patients with proven sarcoidosis have cardiac involvement. MRI is more sensitive than echo in the detection of sarcoid heart disease.

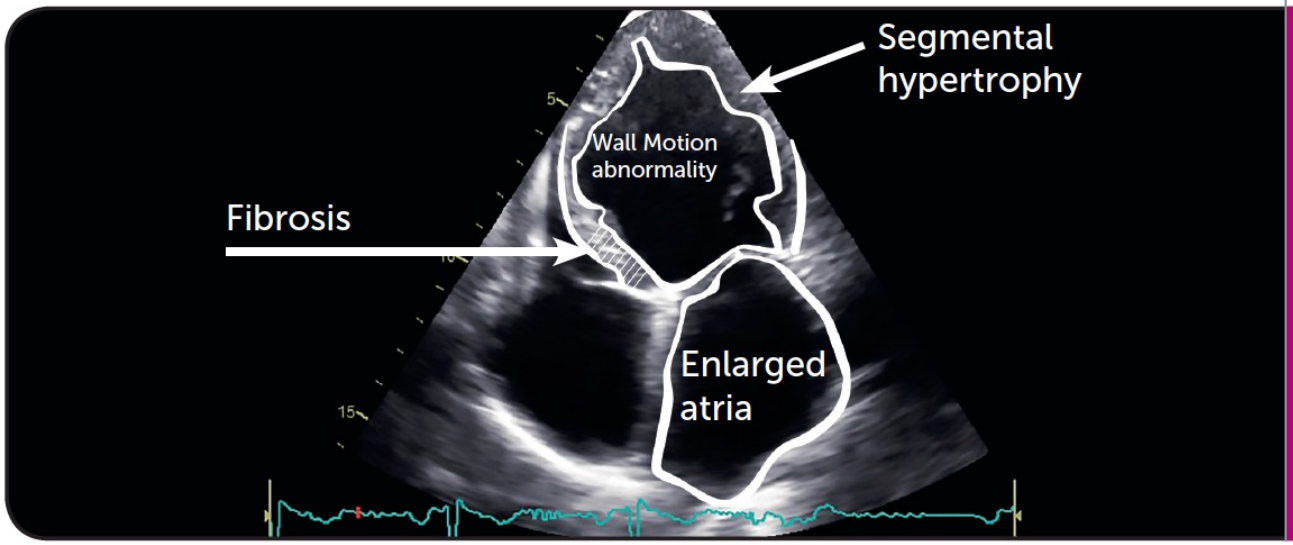


SARCOIDOSIS – apical four-chamber view/2D

Abnormal cardiac geometry with segmental wall motion abnormalities, thickening, and increased echogenicity in the region of the mid- and distal anterior septum.

# Carcinoid heart disease.

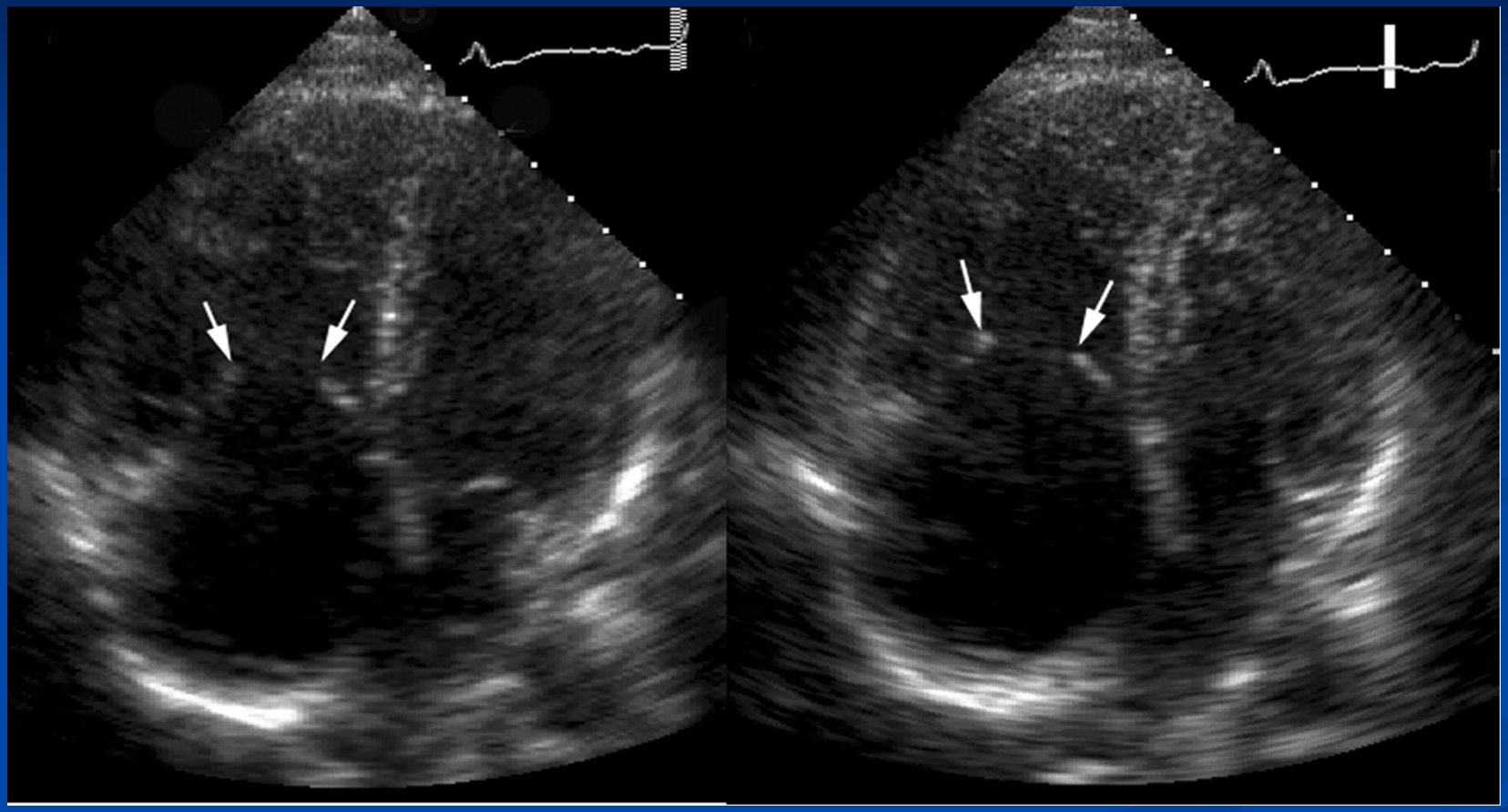

Scarsbrook A F et al. Radiographics 2007;27:455-477

RadioGraphics

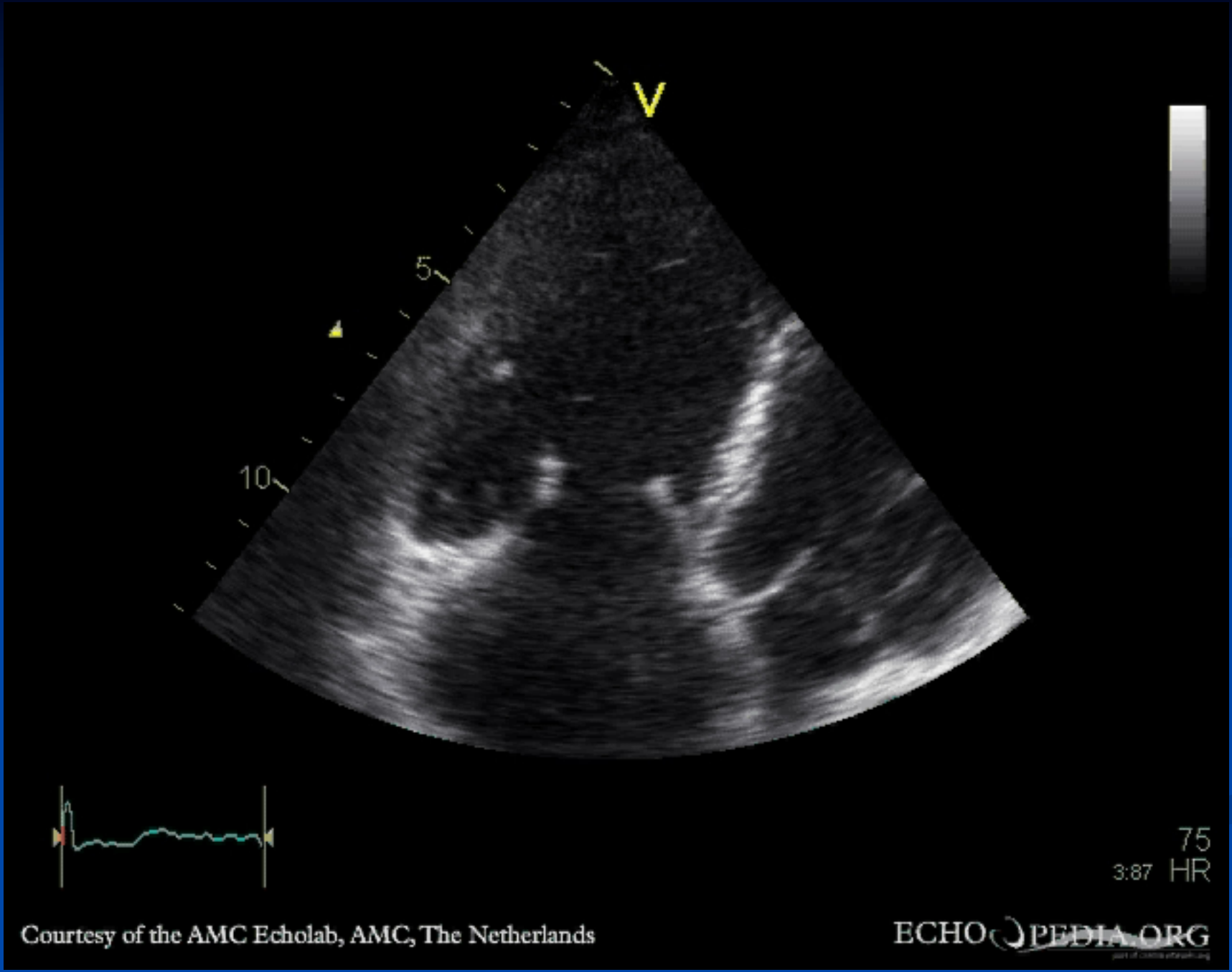
V
5
10
75
3:87 HR
Courtesy of the AMC Echolab, AMC, The Netherlands
ECHOPEDIA.ORG

# Mitrális "A" hullám és PV "a" hullám

- **Restrictive Physiology:**
  - PV-a Velocity > 35 cm/s

  OR

  - PV-a duration, 30 ms longer than Mitral "A" wave duration.

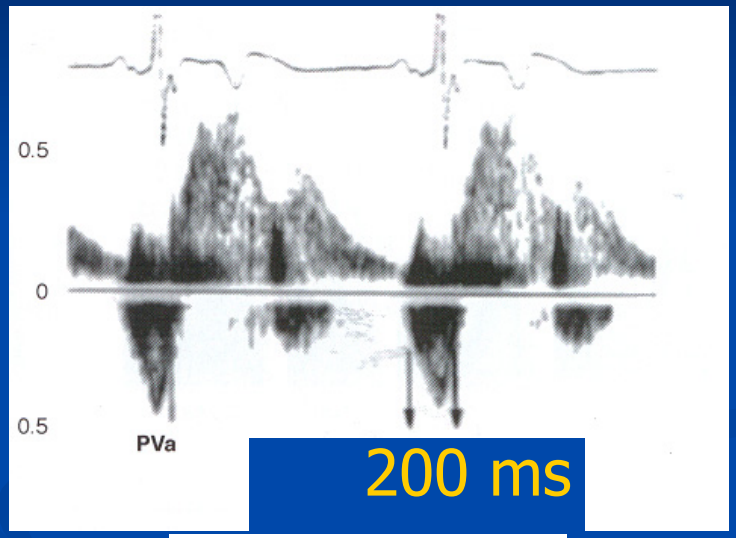


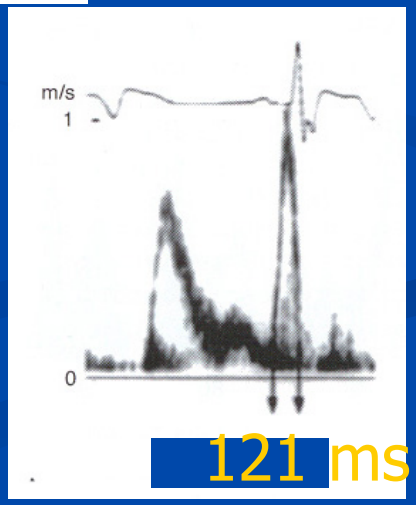

# Hepatic Vein Dopplar: Normal

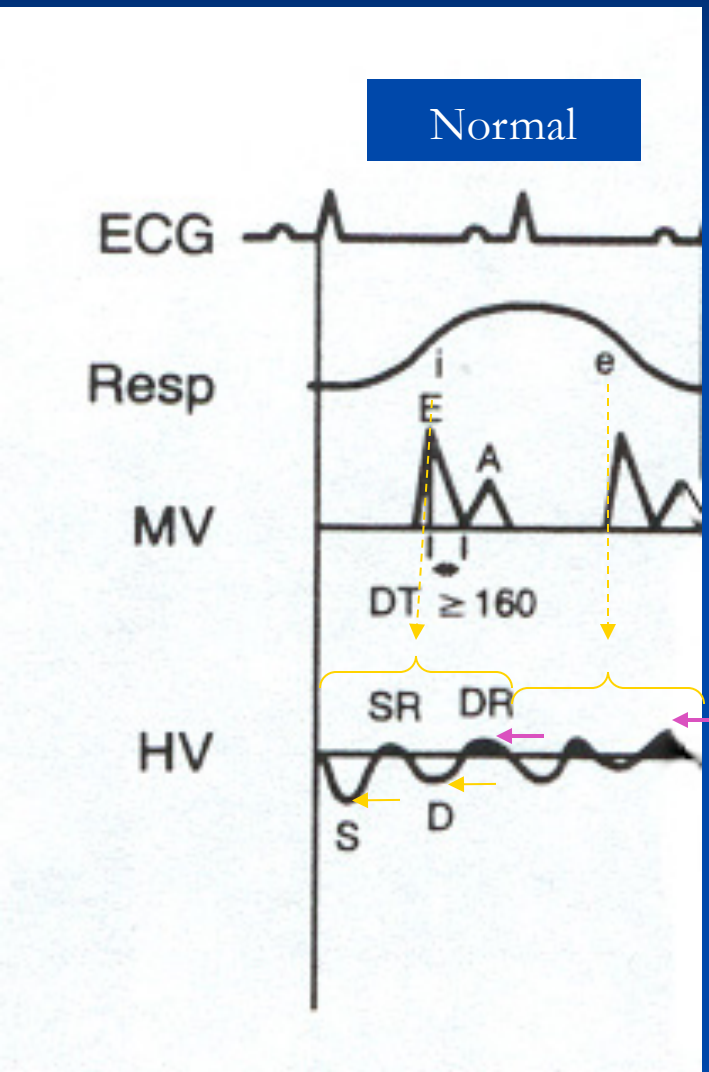


Systolic and diastolic forward flow

S-vel. > D-vel.

Diastolic flow reversal:

Expir.>>Insp.

# Máj vény Doppler: Restriction

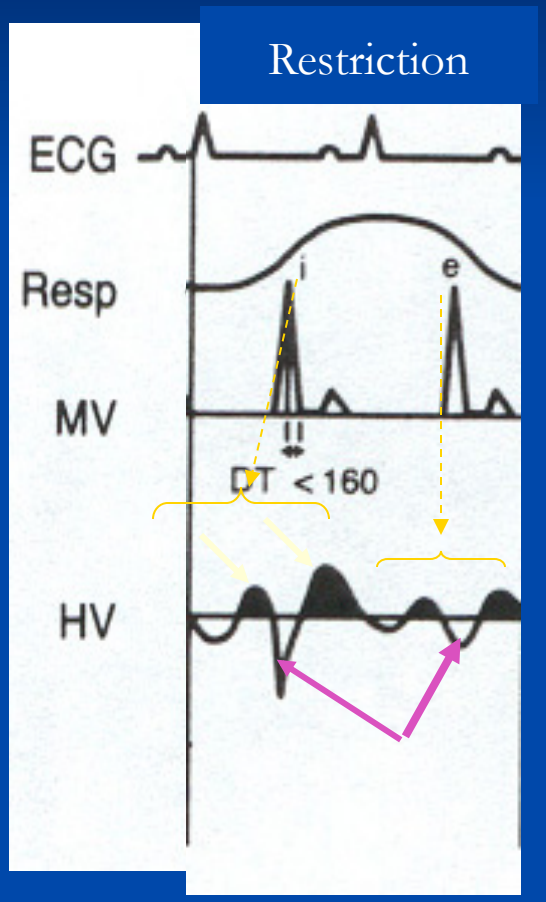


Forward flow primarily in Diastole.

Inspiration increases both
>systolic, and
>Diastolic
Flow reversals.

# Constictiv pericarditis

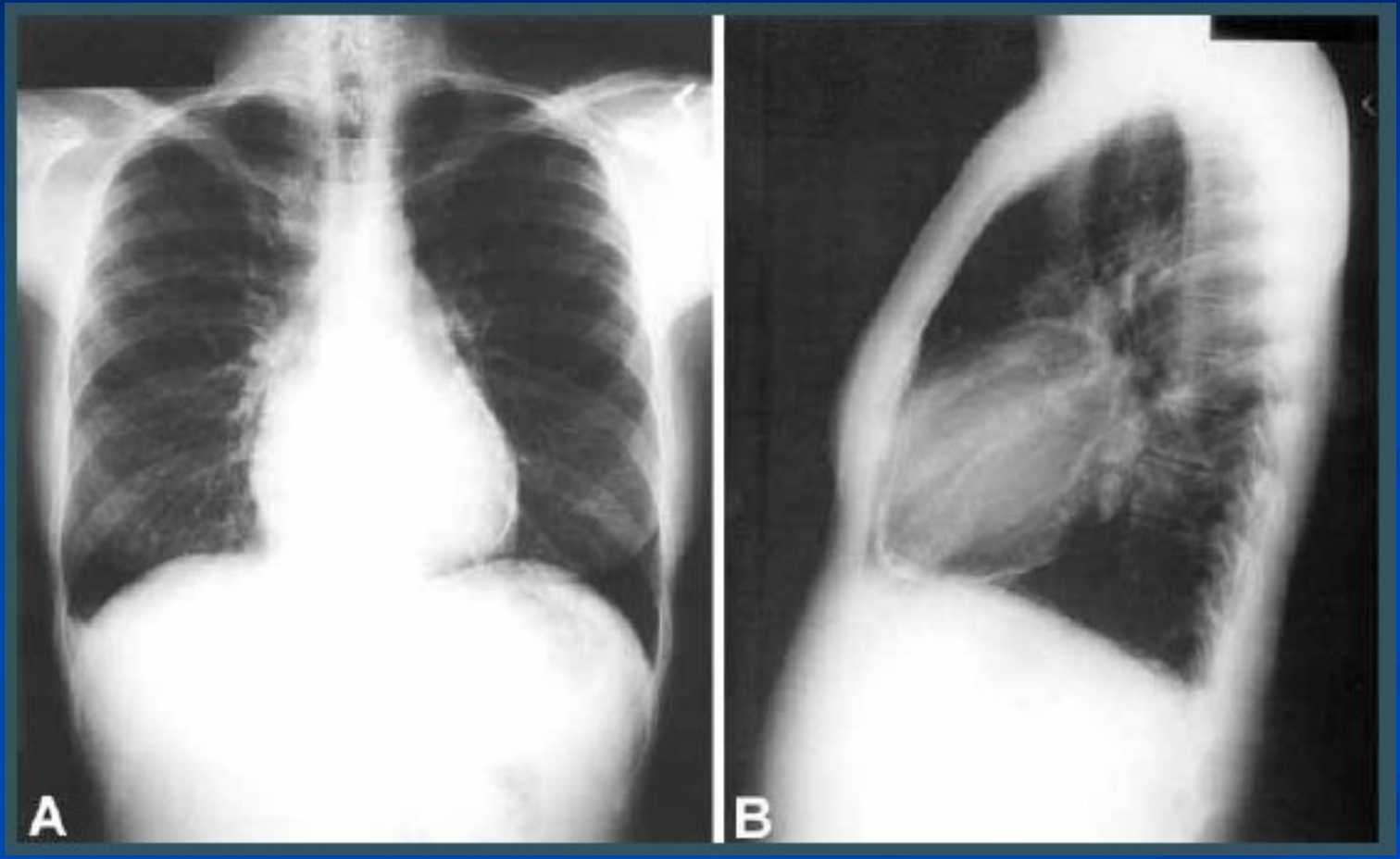

# Constrictiv vagy restrictiv folyamat? Szöveti Doppler!

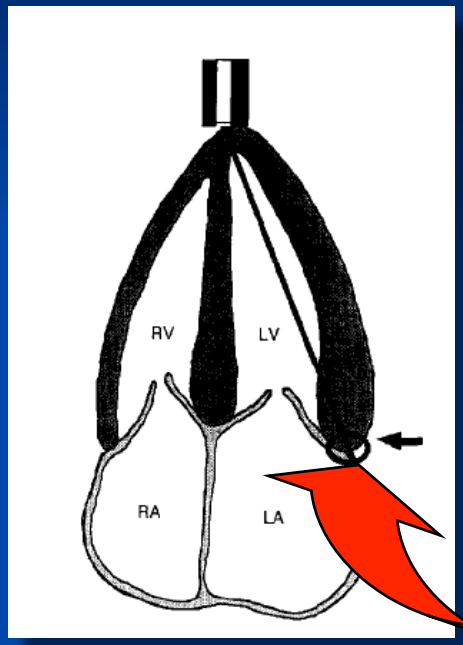


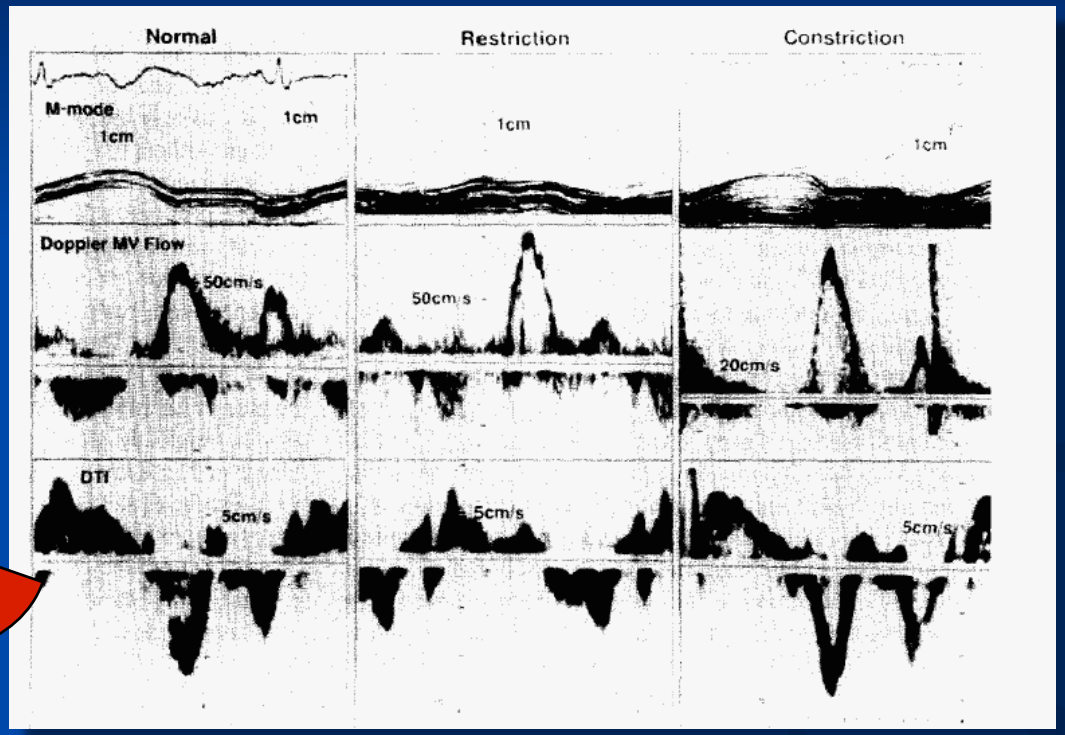


- Az anuluson mért kora diasztolés sebesség restrictiv cardiomyopathiában csökkent, míg pericardiális constrictioban normális

Garcia et al. JACC 1996;27:108-14.

# Májvéna Doppler: Constriction

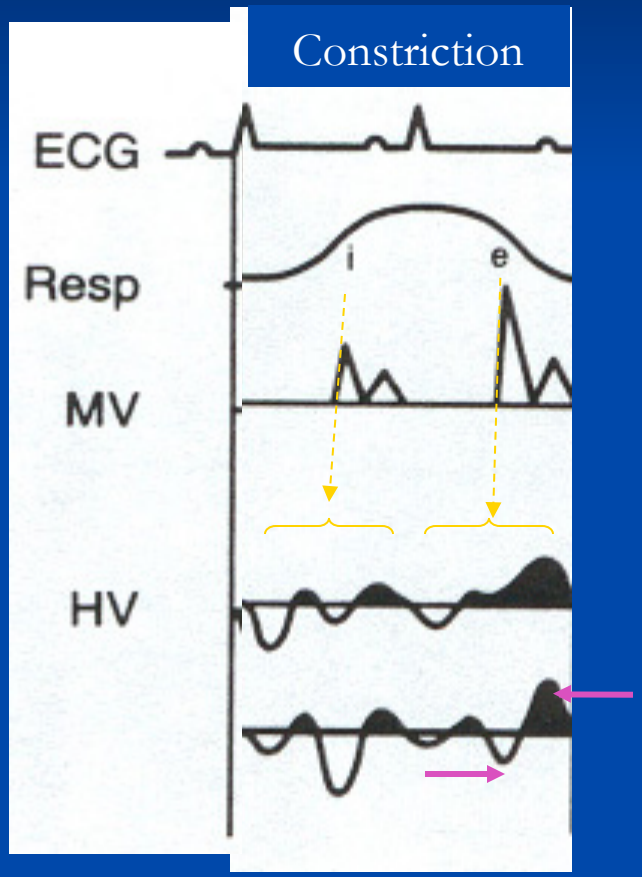


Diastolic flow reversal is augmented in **expiration**.

$DFR_{exp.}$ >25% forward diastolic velocity

# Constriction Doppler

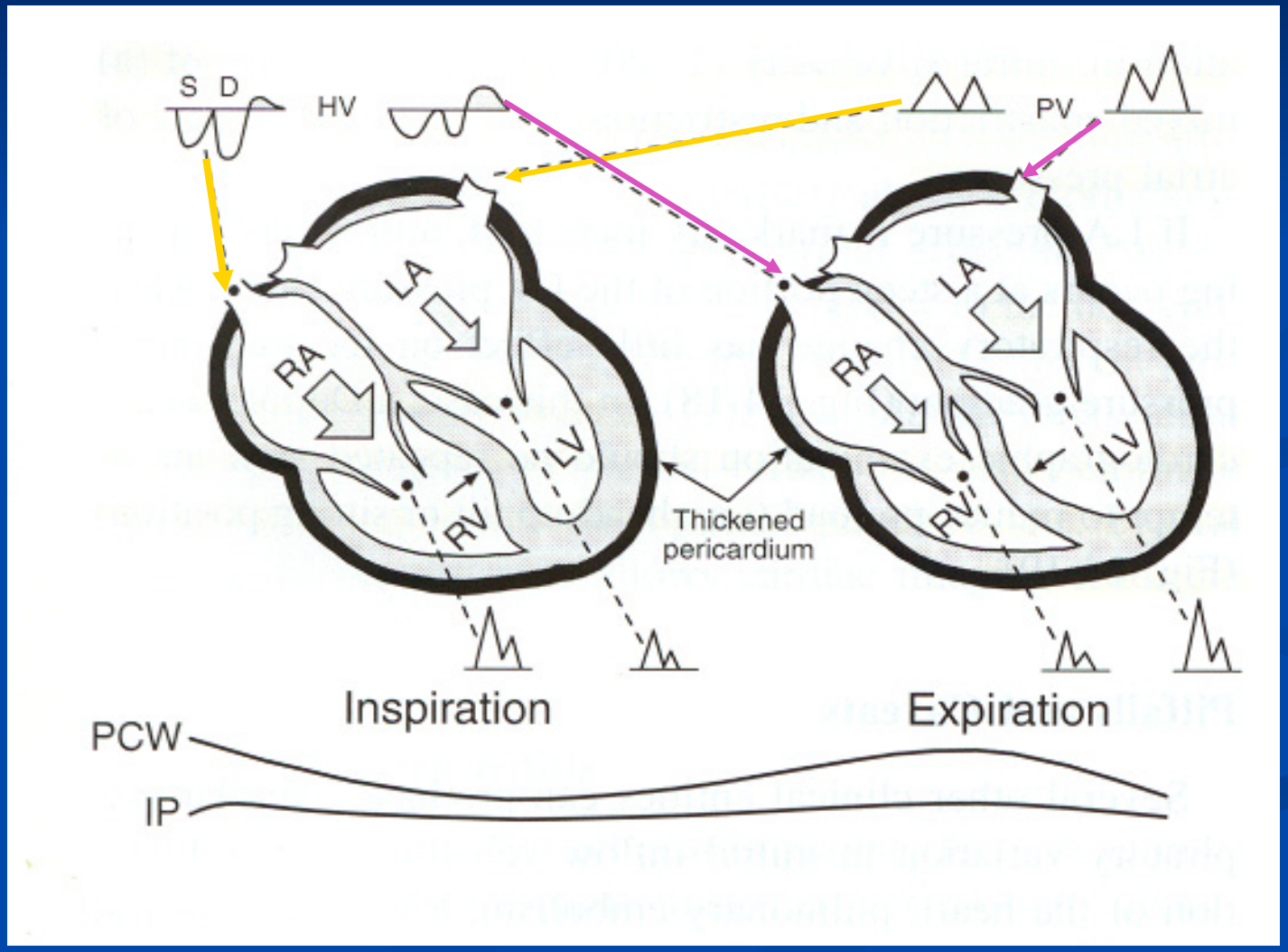


vu sur
Humour.com

# Pericardialis tamponade

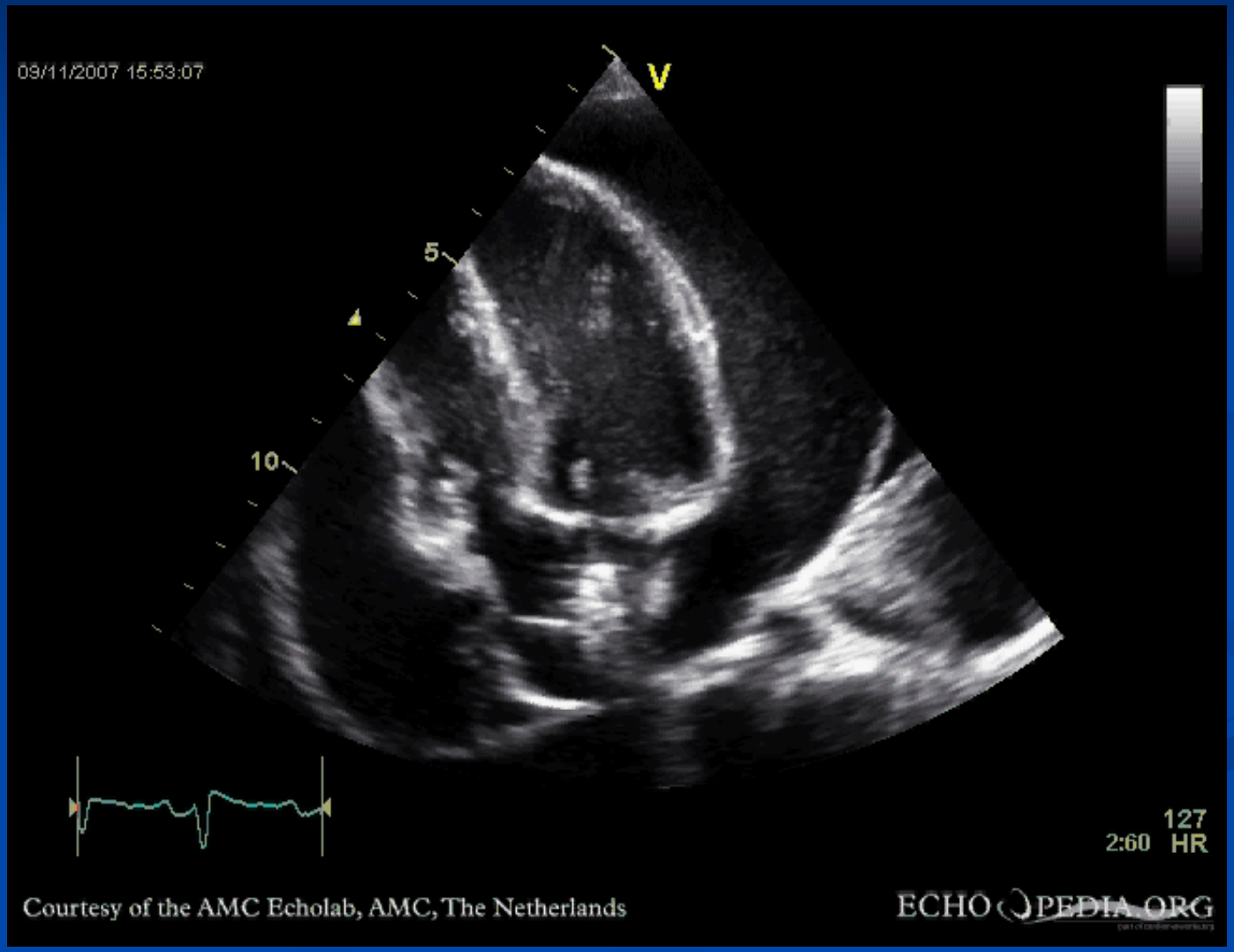

# Tamponade - Paradox pulsus

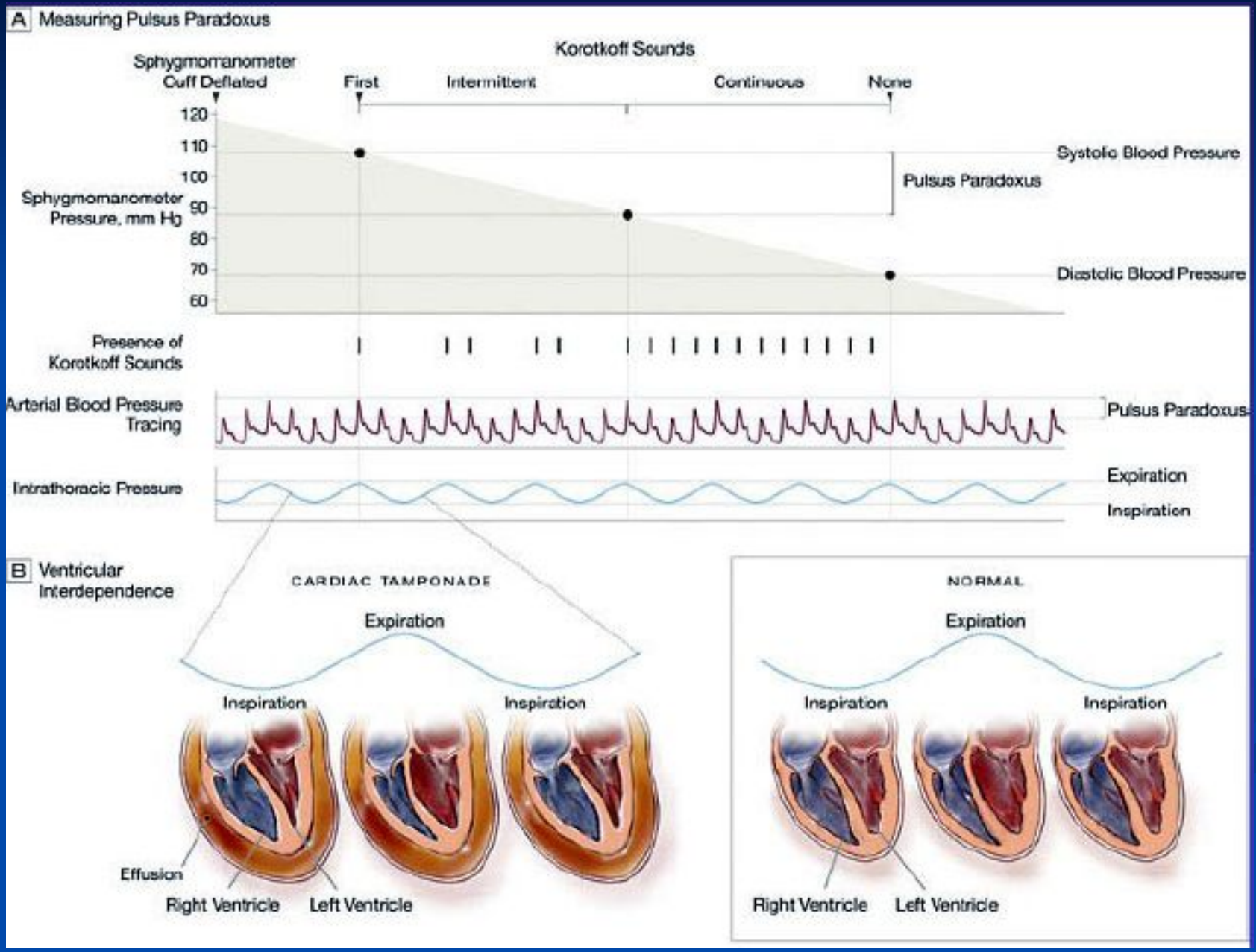

# ARVD - MRI

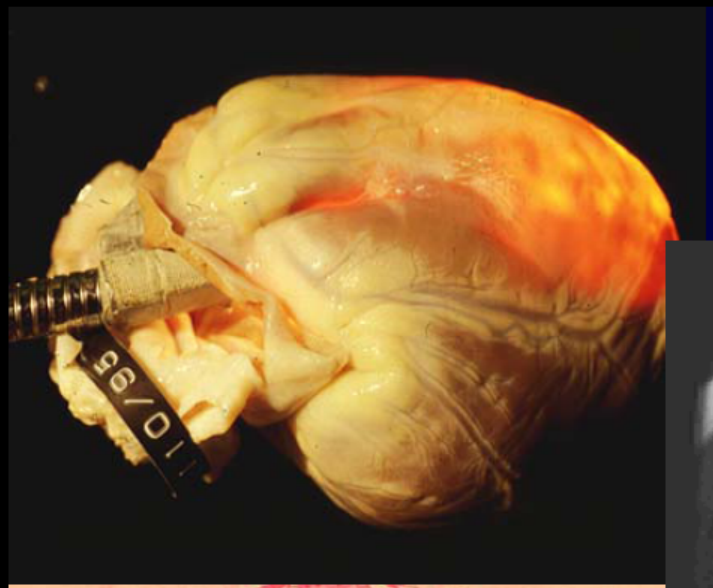

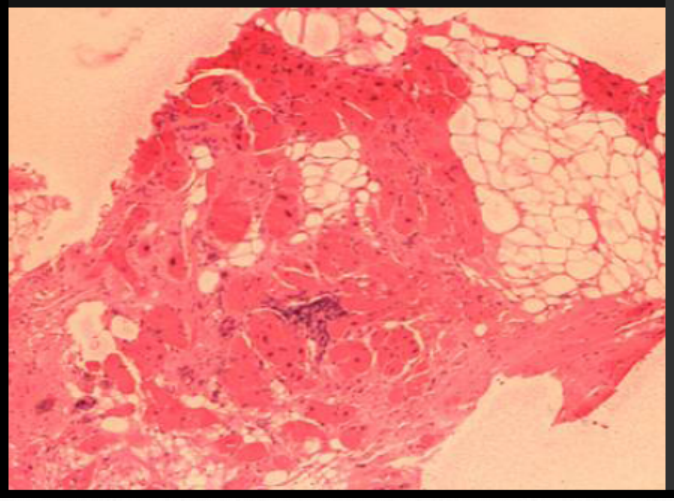

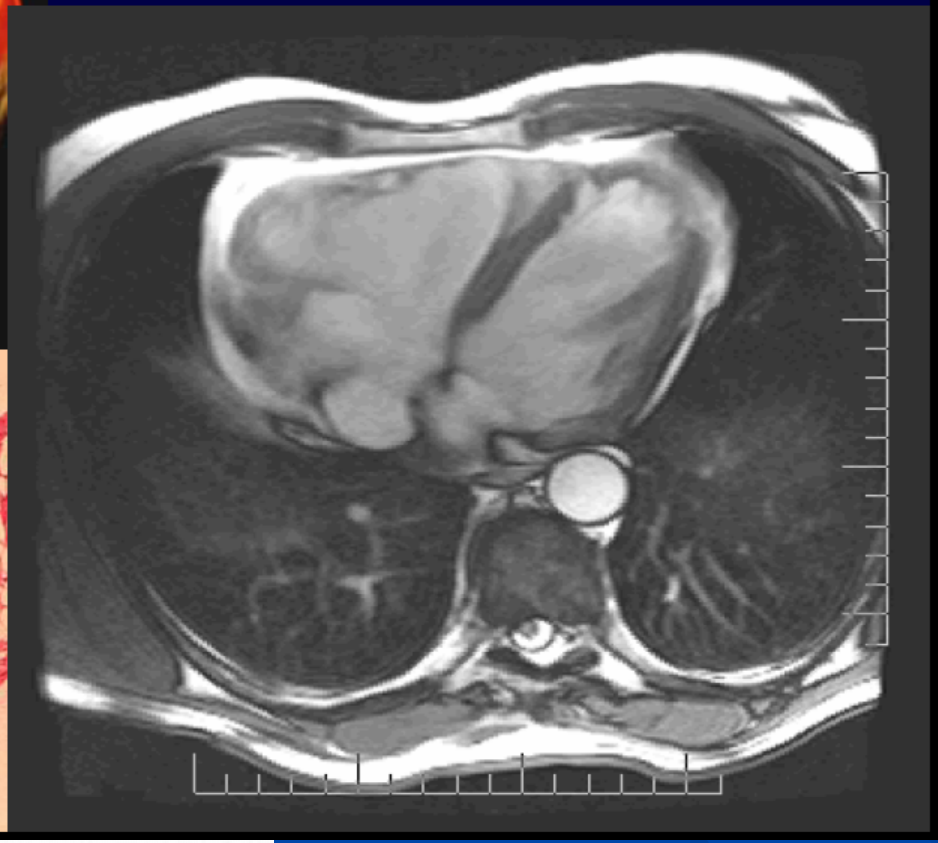

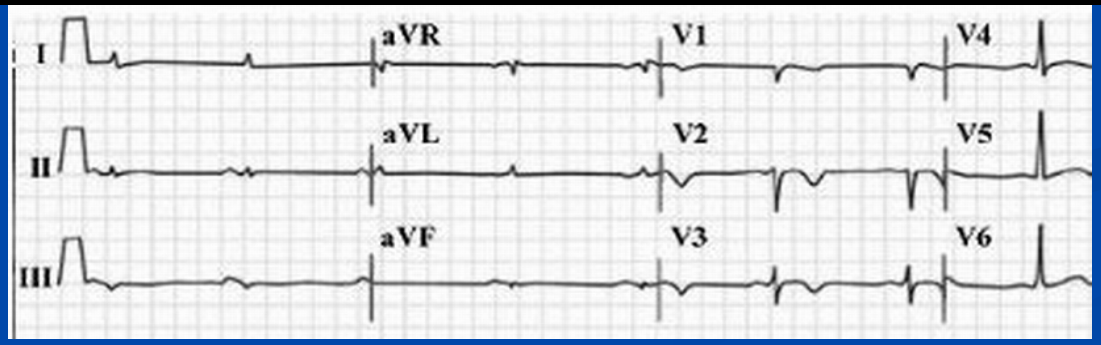


**1:5000**
**Genetika (desmosoma)**

# ARVD 2D echo eltérések

Echocardiographic views from probands meeting Task Force Criteria for arrhythmogenic right ventricular (RV) dysplasia

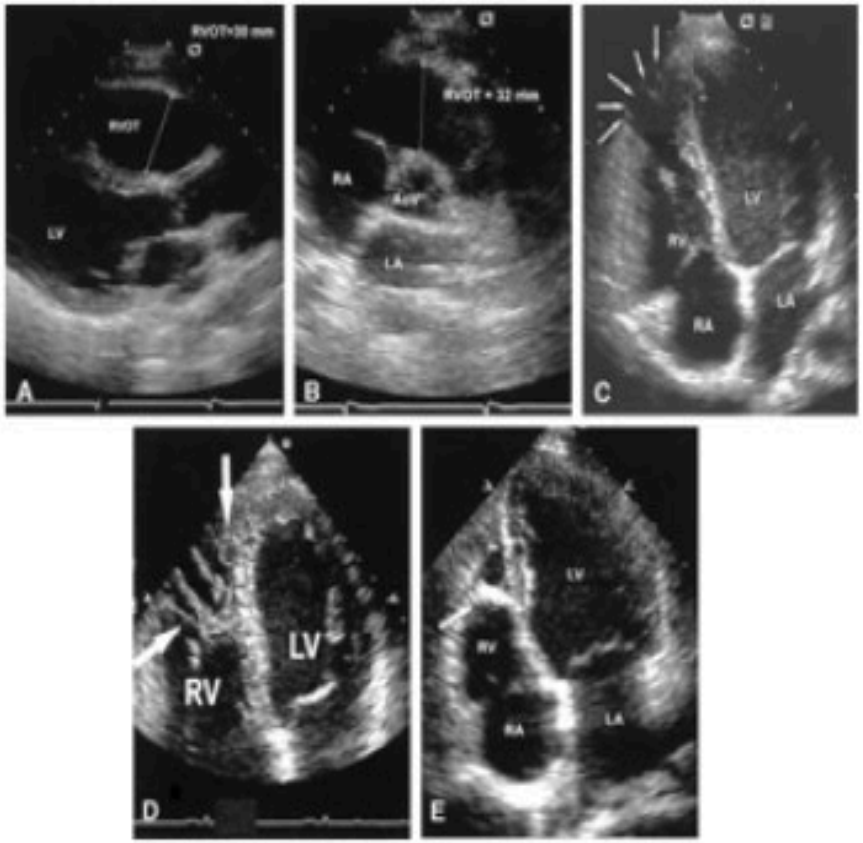


Yoerger, D. M. et al. J Am Coll Cardiol 2005;45:860-865

- -segmental RWMA
- -focal RV aneurysms
- -RVOT/RVIT dilatation
- -RV systolic dysfunction
- -trabecular derangement
- -moderator band hyper-reflectivity

# ARVD

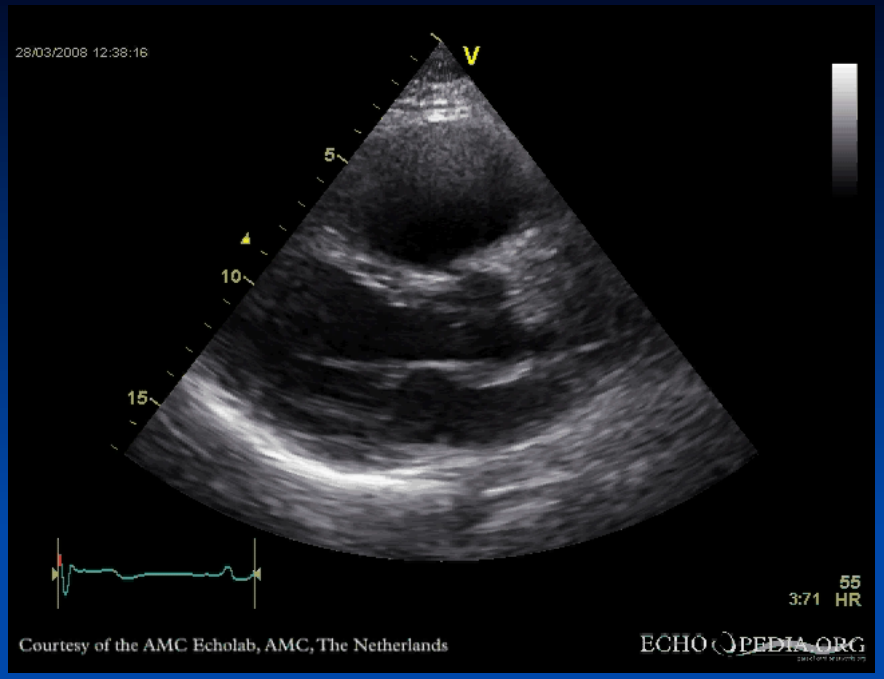
28/03/2008 12:38:16
V
5
10
15
55
3:71 HR
Courtesy of the AMC Echolab, AMC, The Netherlands
ECHOPEDIA.ORG

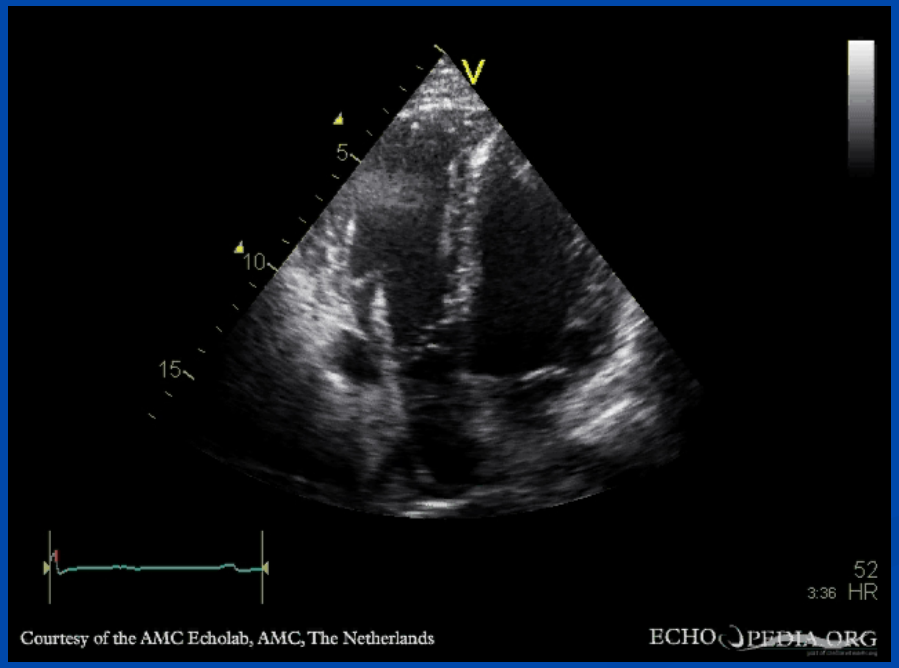
V
5
10
15
52
3:36 HR
Courtesy of the AMC Echolab, AMC, The Netherlands
ECHOPEDIA.ORG

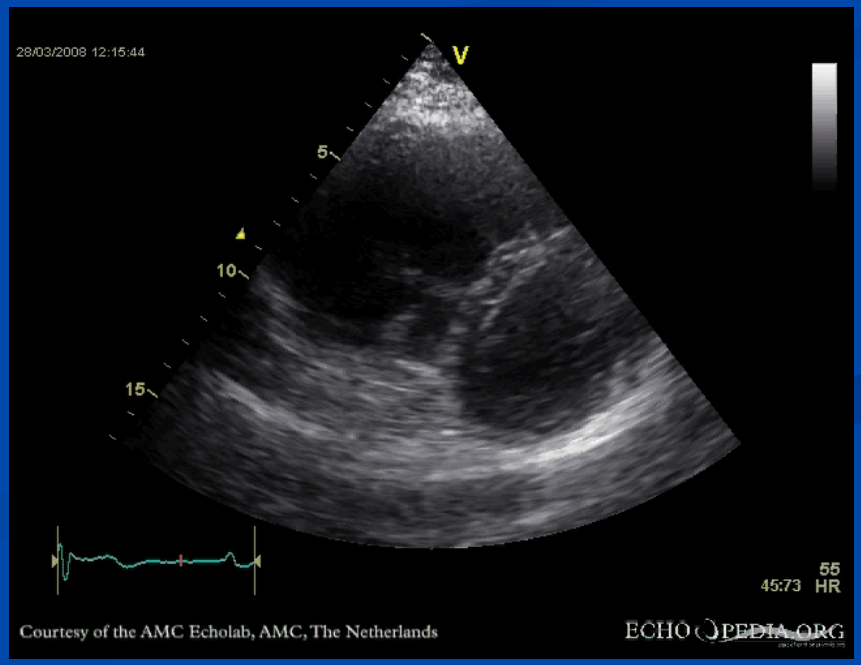
28/03/2008 12:15:44
V
5
10
15
55
45:73 HR
Courtesy of the AMC Echolab, AMC, The Netherlands
ECHOPEDIA.ORG

# Global or regional dysfunction or structural alterations

## *Modified Task Force Criteria*

### Major **(By 2D echo)**

- Regional RV akinesia, dyskinesia or aneurysm

  *and* 1 of the following (end diastole)

- ✓ PLAX RVOT≥32mm (≥19mm/m$^2$)
- ✓ PSAX RVOT≥36mm (≥21mm/m$^2$)
- ✓ or fractional area change ≤33%

### Minor **(By 2D echo)**

- Regional RV akinesia, dyskinesia or aneurysm

  *and* 1 of the following (end diastole)

- ✓ PLAX RVOT≥29mm to <32mm (≥16mm/m$^2$ to 19mm/m$^2$)
- ✓ PLAX RVOT≥32mm to <36mm (≥18mm/m$^2$ to 21mm/m$^2$)
- ✓ or FAC >33% to ≤40%

## *Original Task Force Criteria*

### Major

- Severe dilatation and reduction of RV EF with no or mild LV involvement
- Localized RV aneurysms (akinetic or dyskinetic areas with diastolic bulging)
- Severe segmental dilatation of the RV

### Minor

- Mild global RV dilatation and/or EF reduction with normal LV
- Mild segmental dilatation of the RV
- Regional RV hypokinesia

# NEM OSZTÁLYOZHATÓ CMP

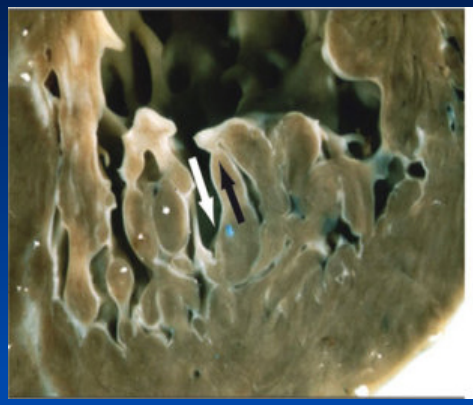

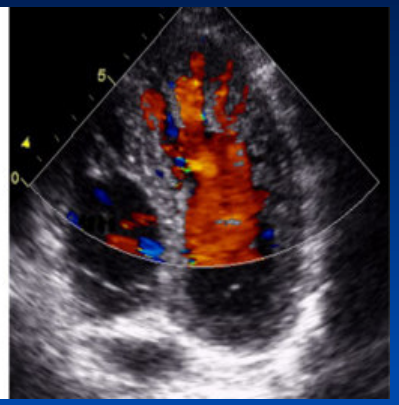

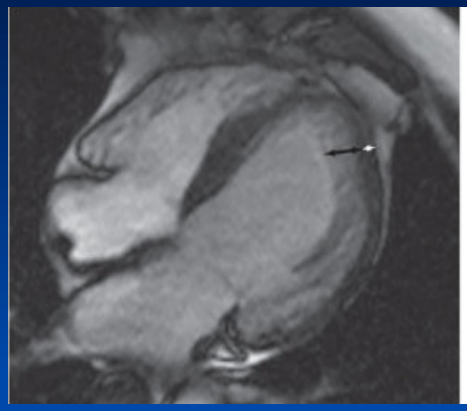

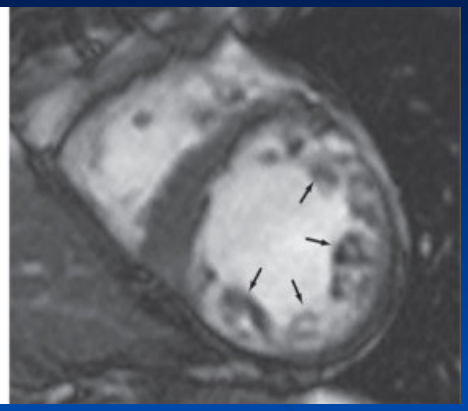

- **Left ventricular non-compaction**
  - **Barth sy. - Tafazzin (X linked)**
  - **Lamin A/C, ZASP, alpha-dystrobrevin**
  - **Echocardiographia (Chin 1990, Jenni 2001)**

- **Tako Tsubo cardiomyopathy**
  - **Magas epinephrin szint pathophysiologiai szerepe**
  - **Lokalizació, MR, Biventricularis**

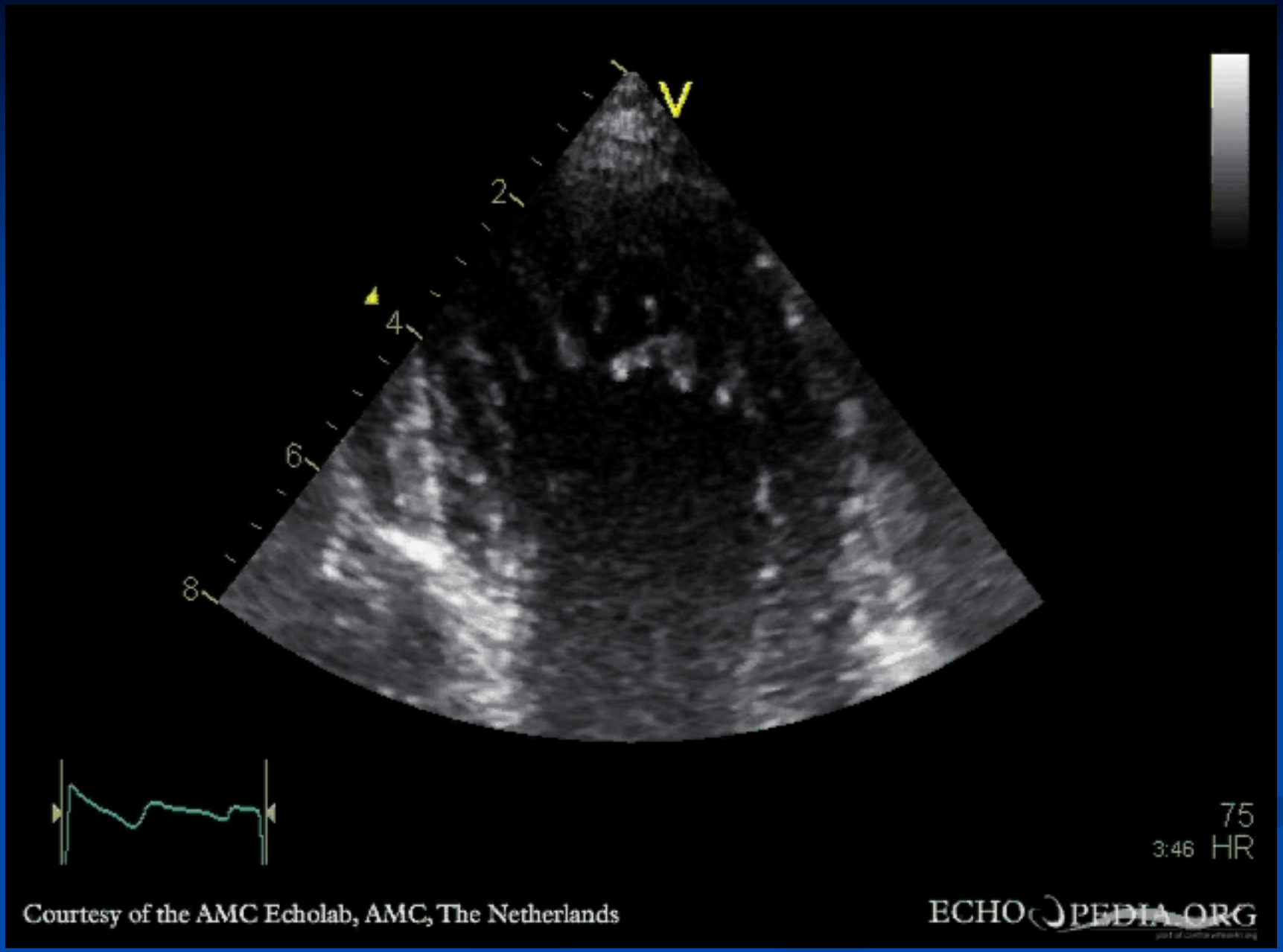
V
2
4
6
8
75
3:46 HR
Courtesy of the AMC Echolab, AMC, The Netherlands
ECHOPEDIA.ORG

# NON COMPACT CMP

**Chin 1990**

1. multiple trabeculations
2. two-layer structure
3. X to Y ratio < 0.5
4. SA and apical views

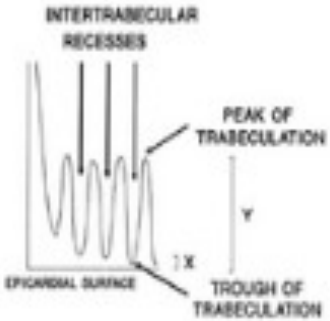


**Jenni 2001**

1. multiple trabeculations
2. deep recesses
3. two-layer structure
4. NC / C ratio > 2
5. Parasternal SA view

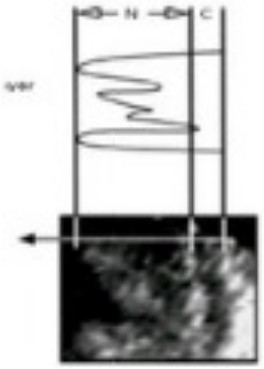

**Stöllberger 2002**

1. > 3 trabeculations
2. Apically to the PM
3. In 1 image plane
4. Intertrabecular spaces
5. Apical views

# Speckle tracking

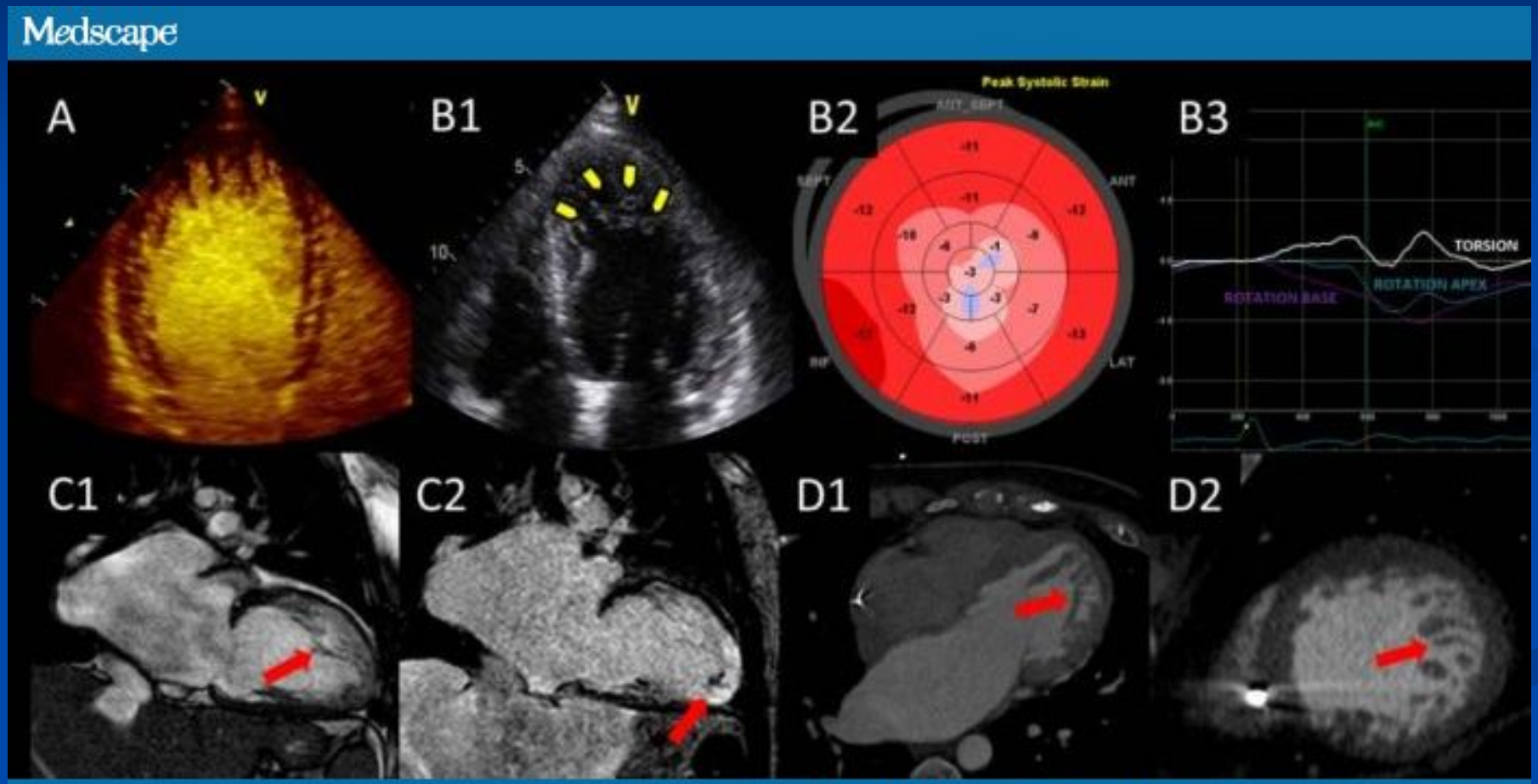


Source: Heart © 2013 BMJ Publishing Group Ltd & British Cardiovascular Society

# TAKO-TSUBO (STRESS) CMP

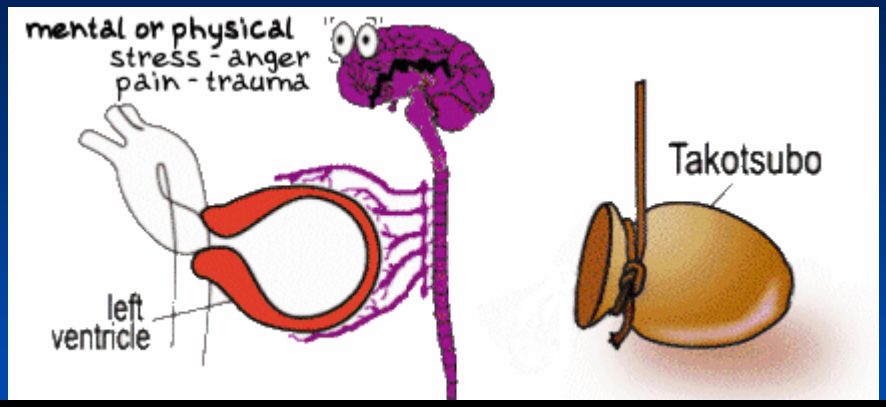


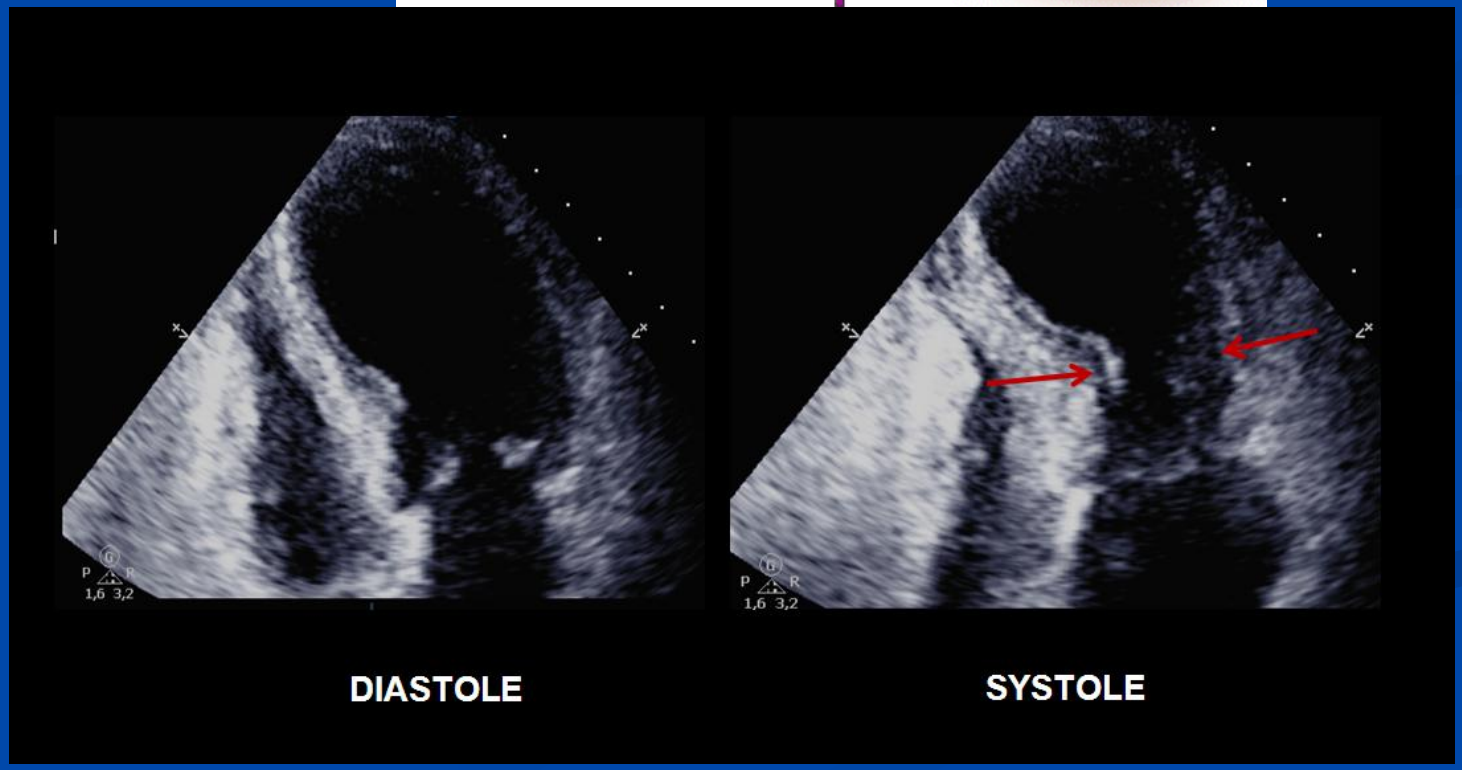

# Köszönöm a figyelmet!